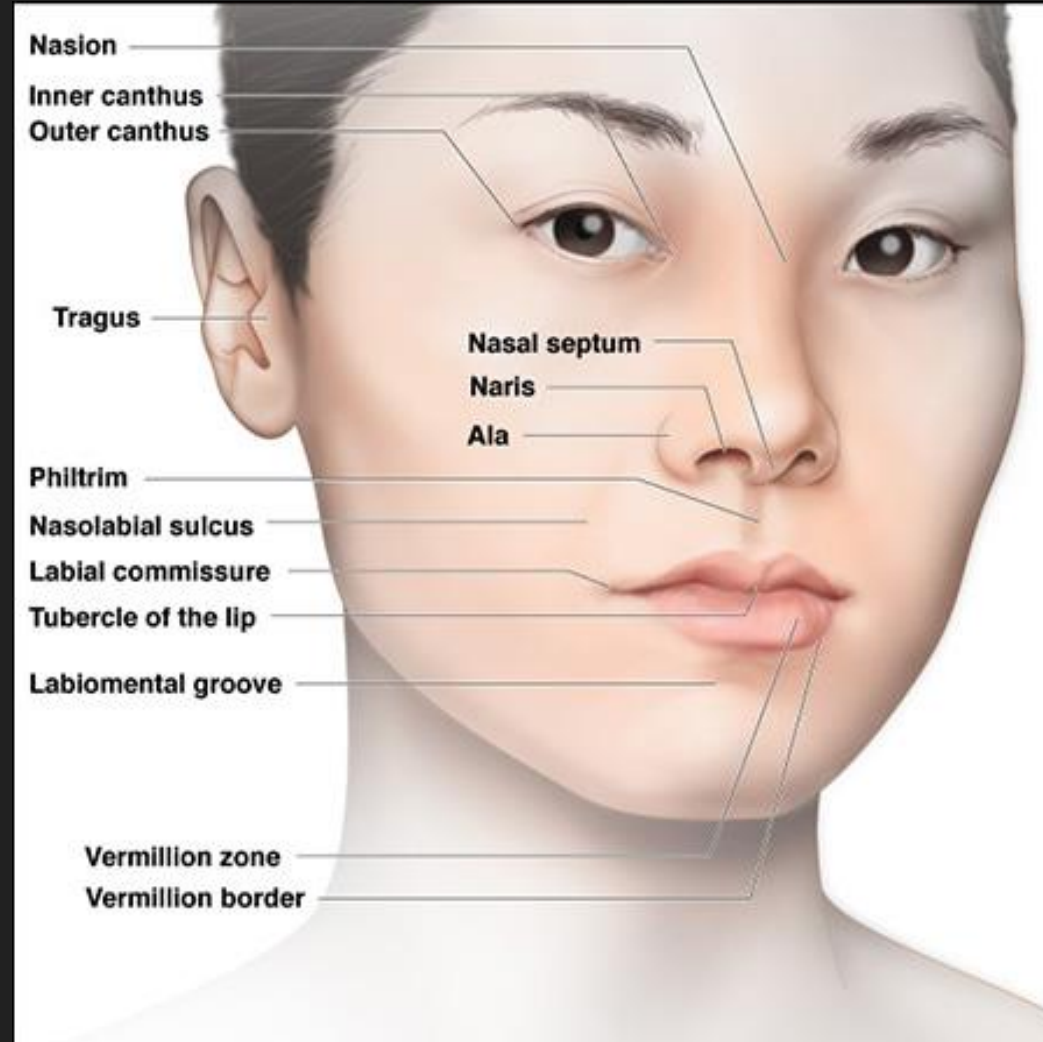


INTRAORAL EXAMINATION

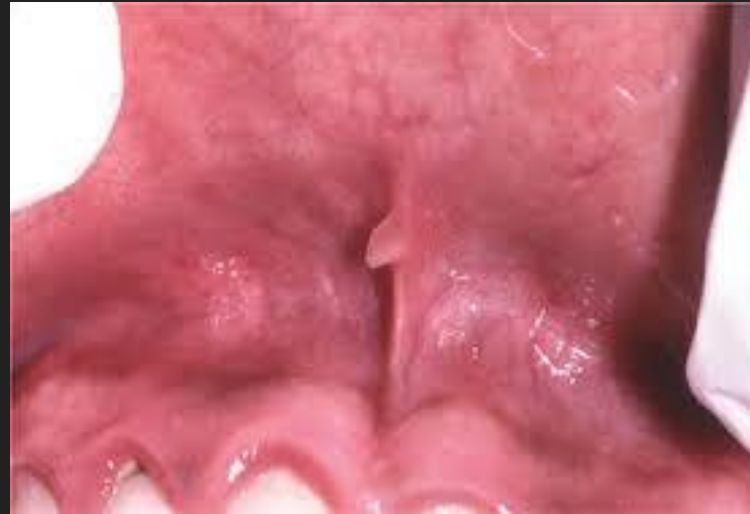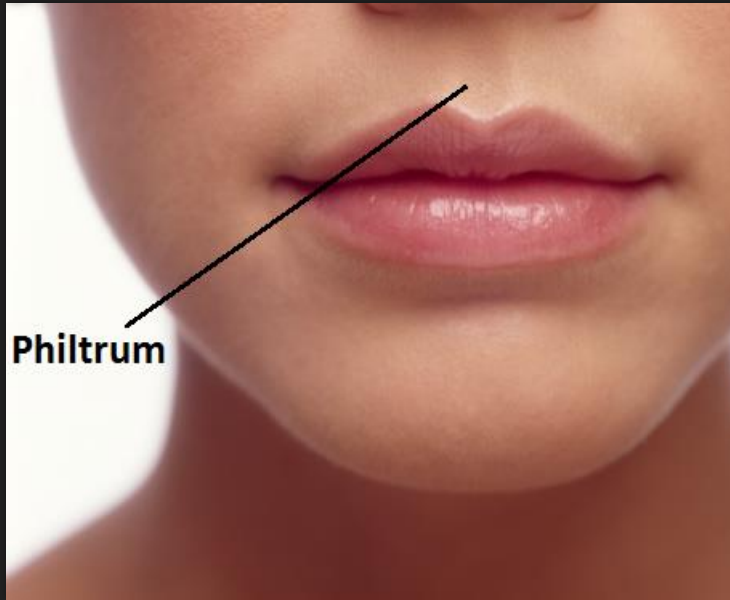
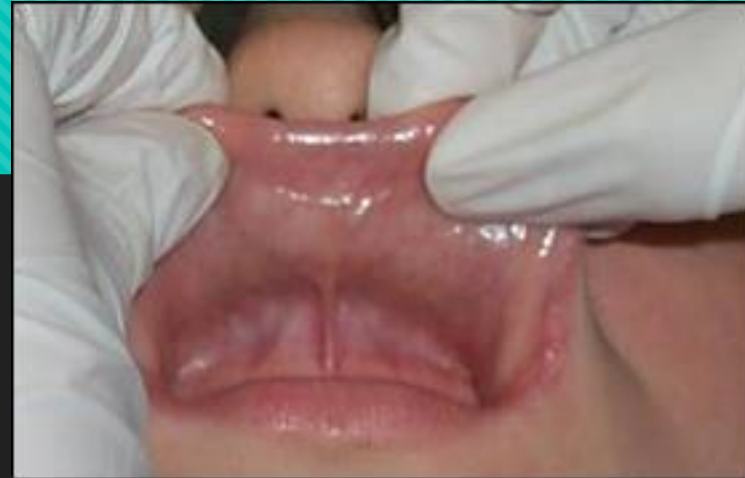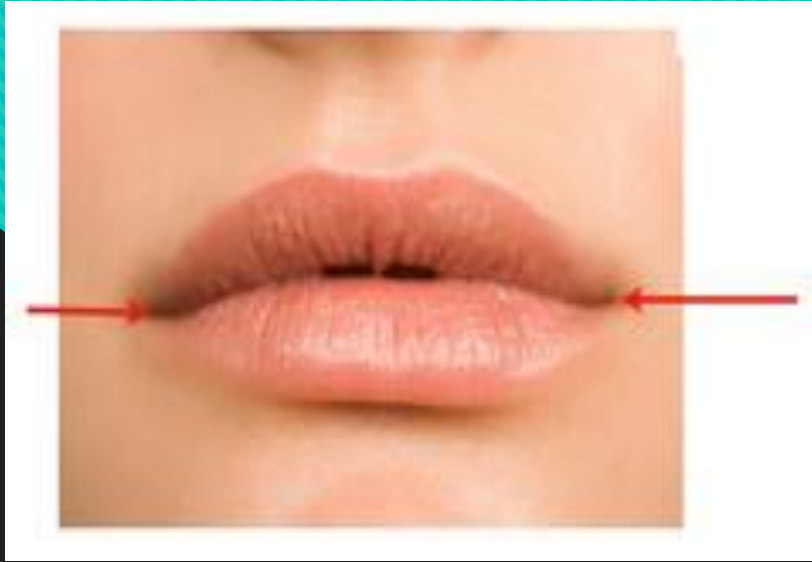


Anatomic landmarks

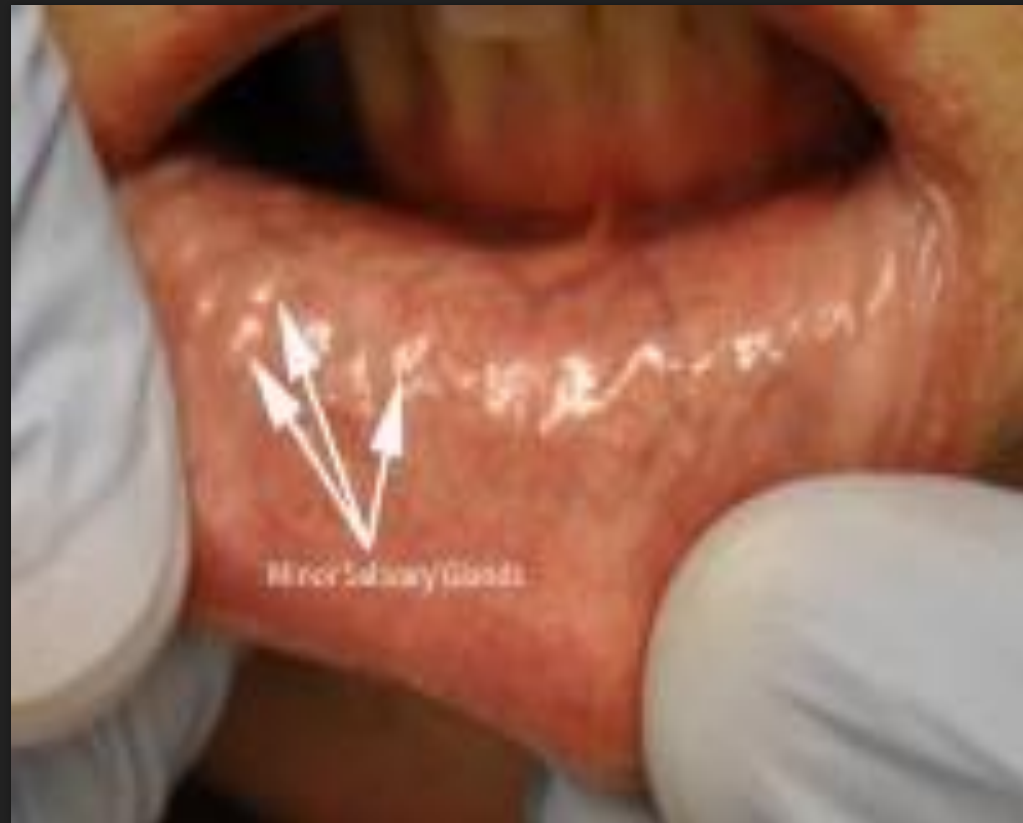Face



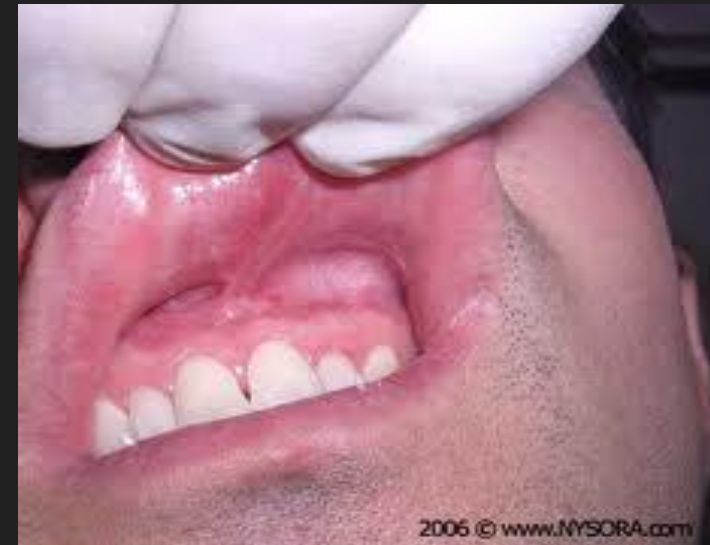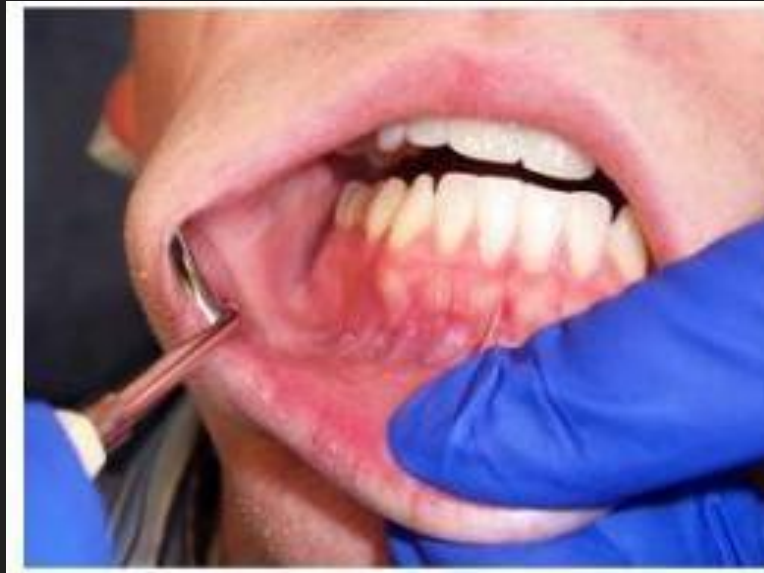Lips



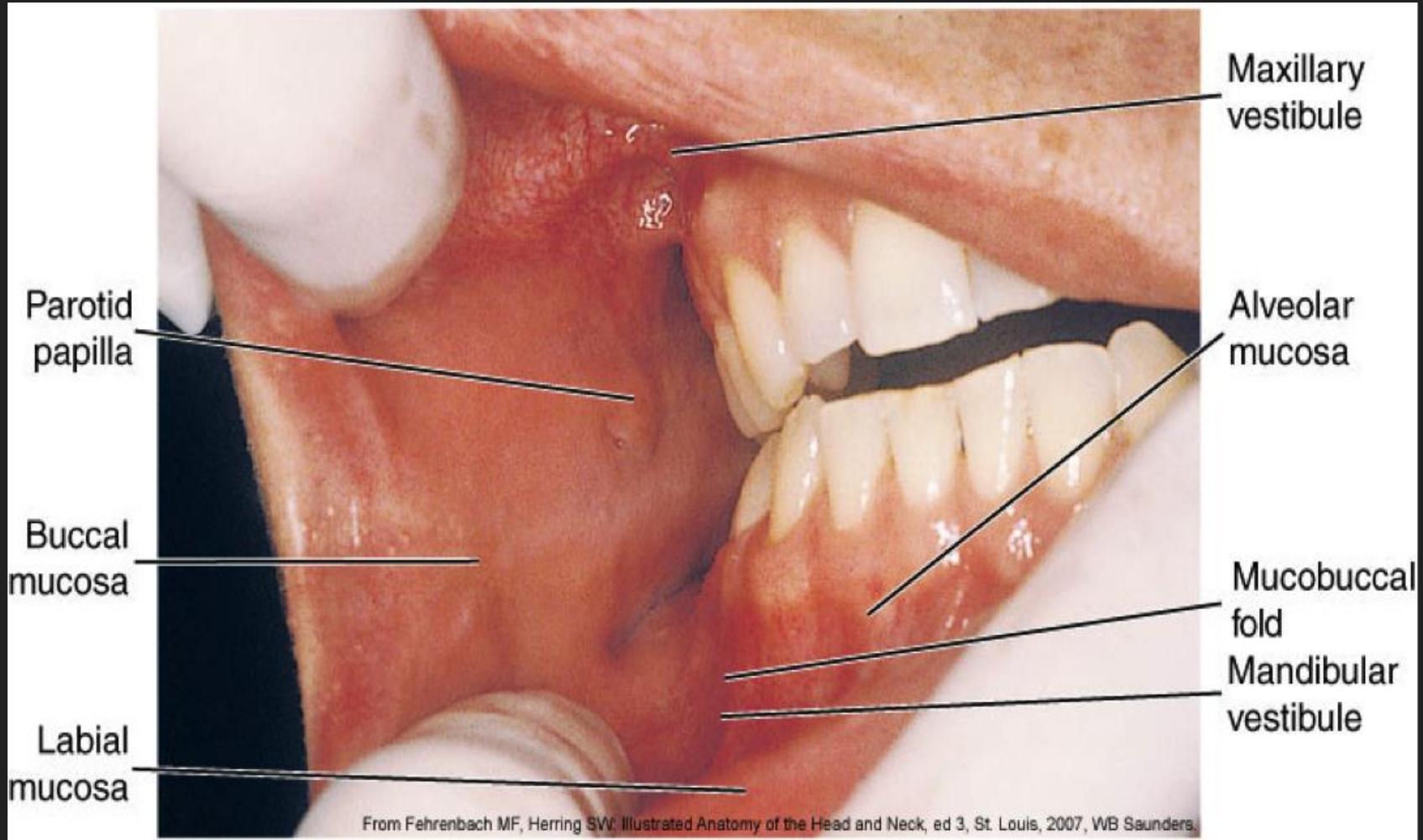
Minor salivary gland



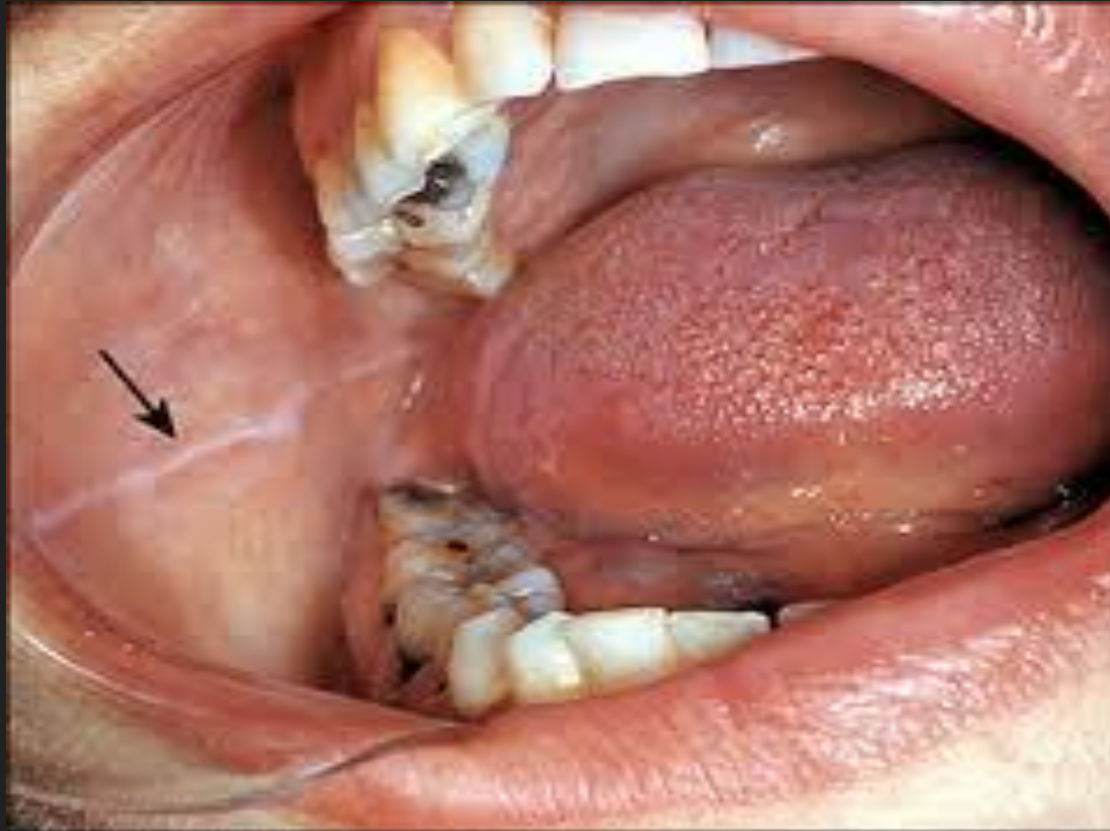Mucobuccal fold



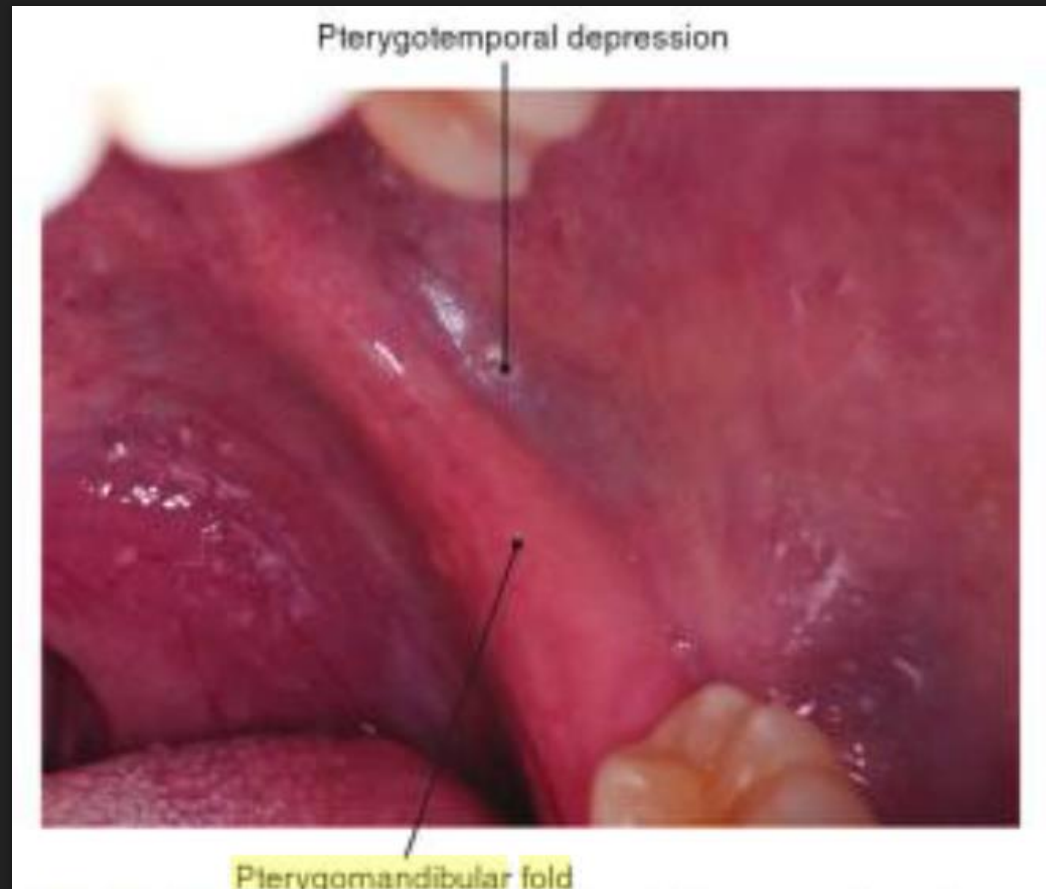Buccal



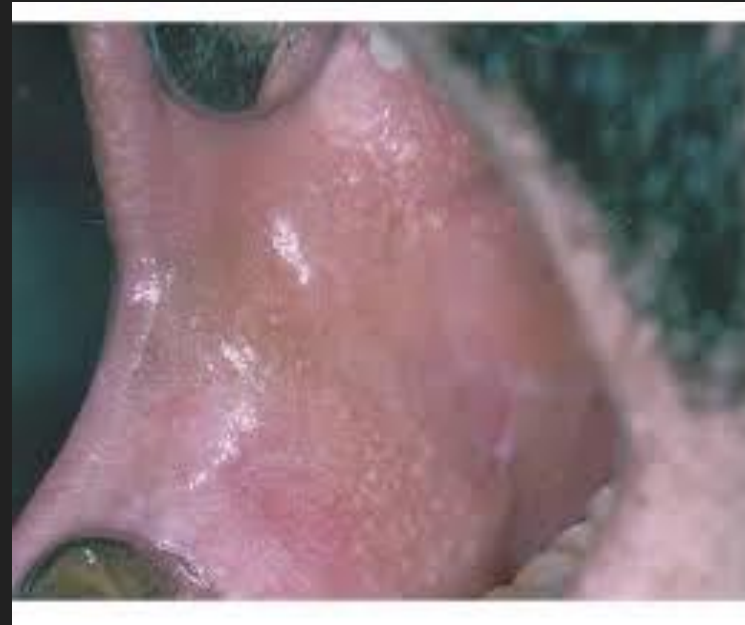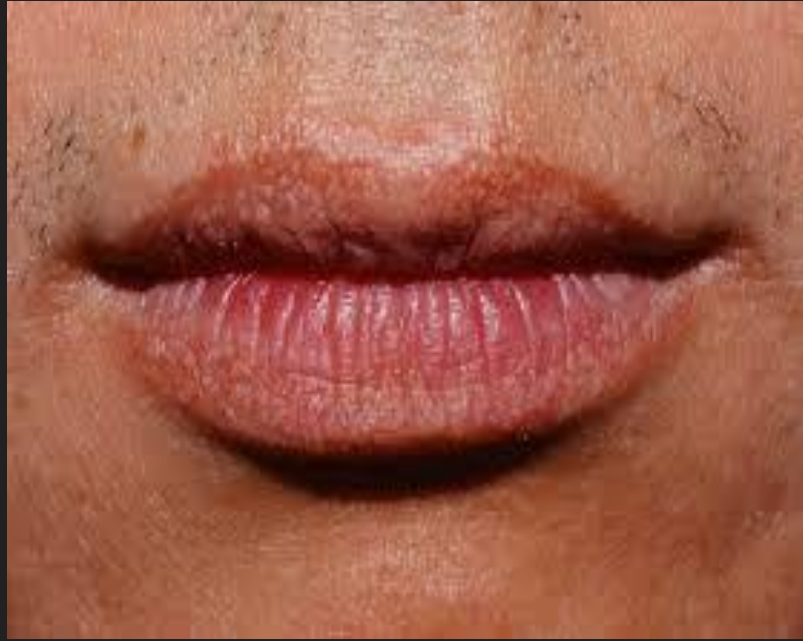Lina alba



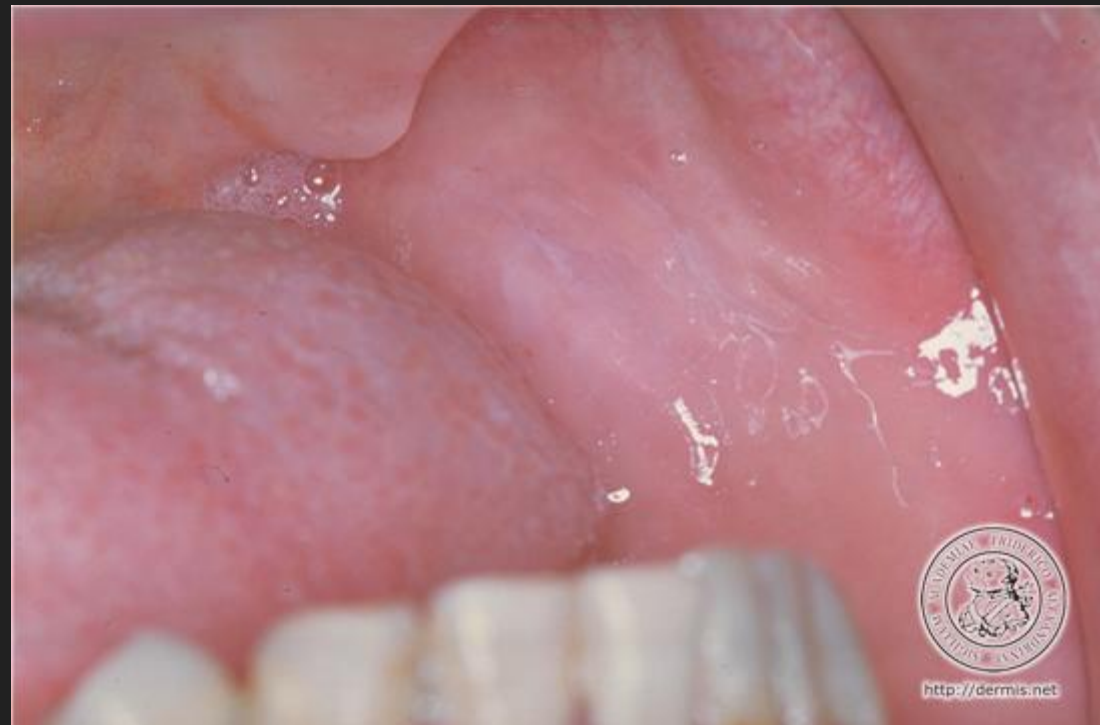Pterygomandibular raphe

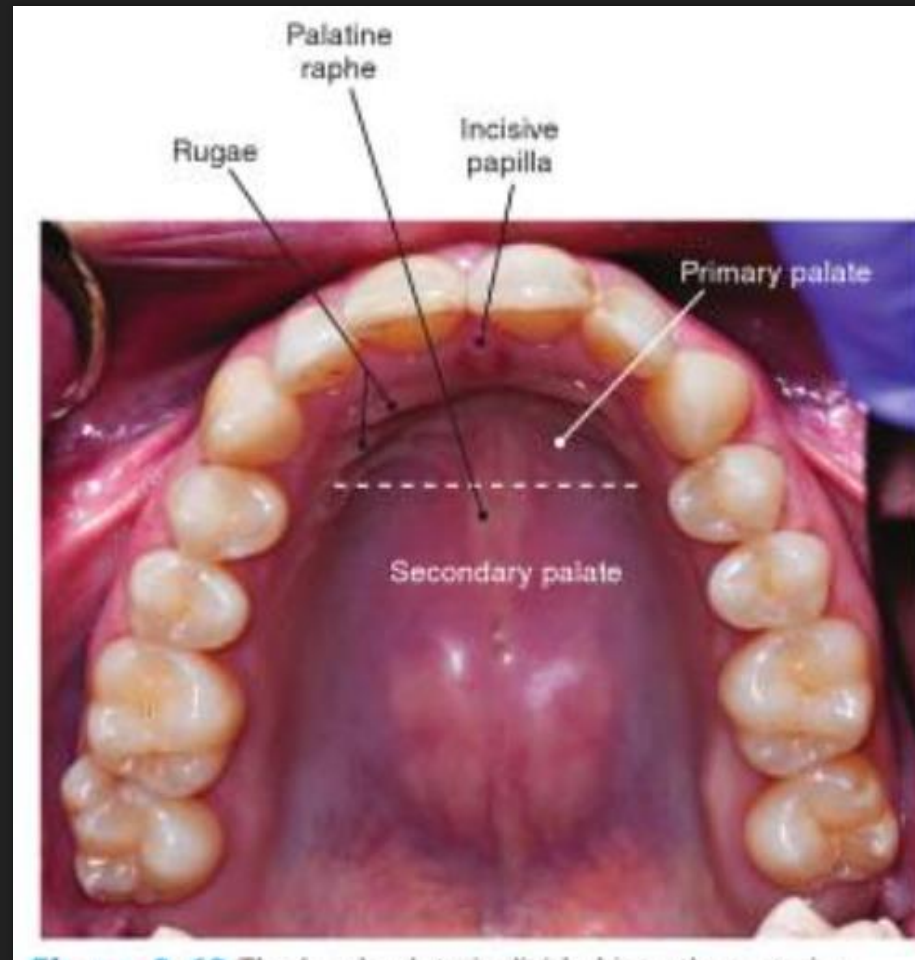


Fordyce granule

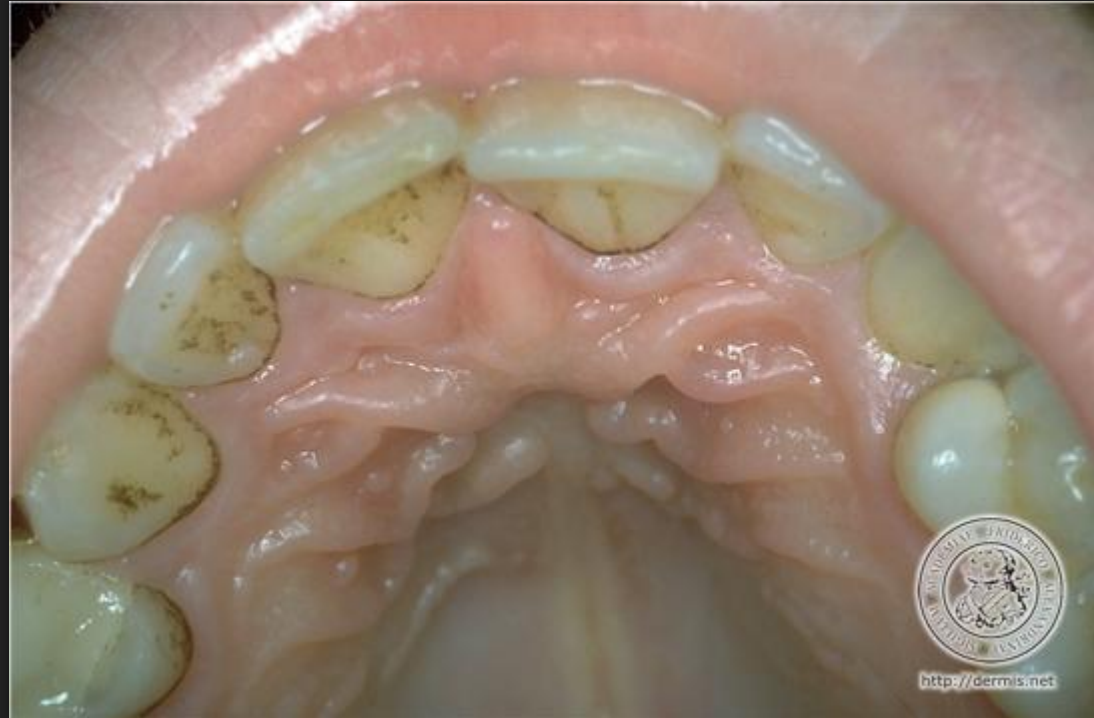

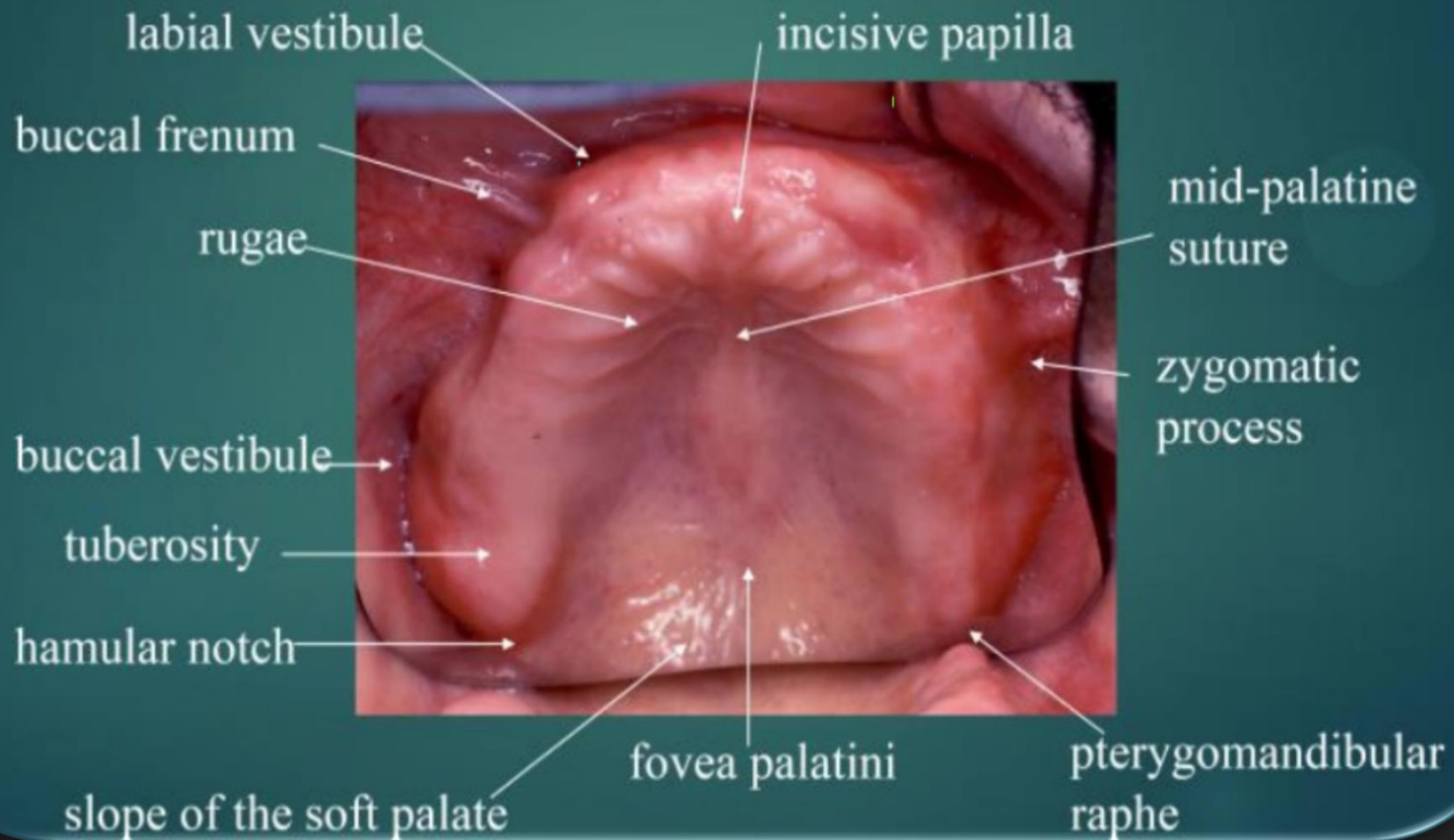
Leukoedema



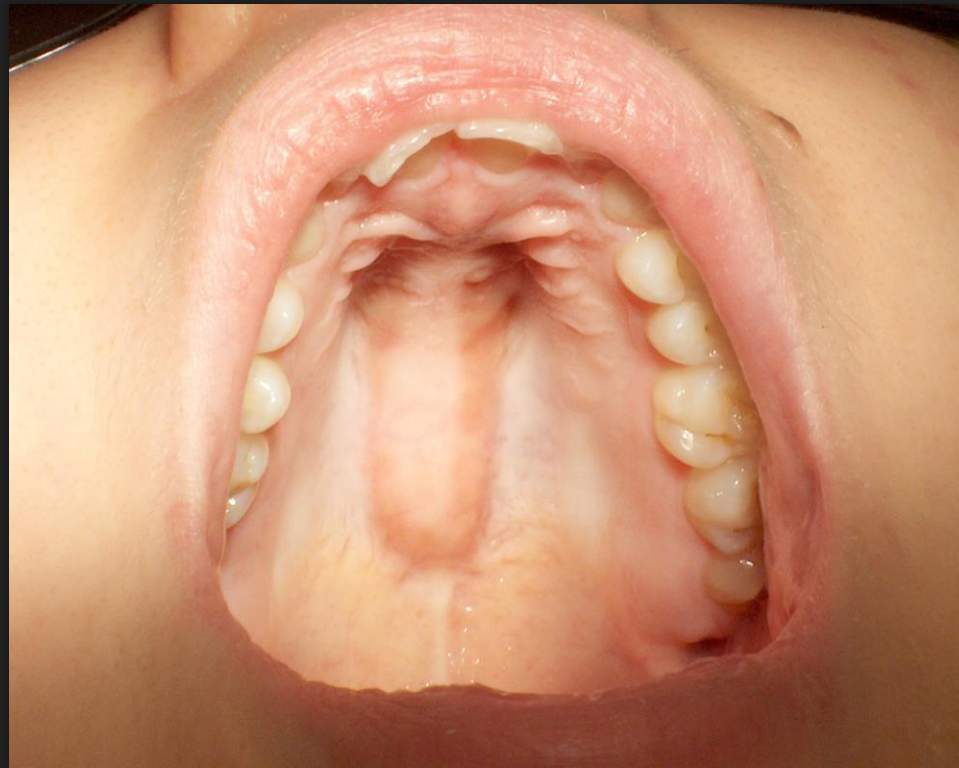

Palatal rugae





Torous palatinus



Pharynx

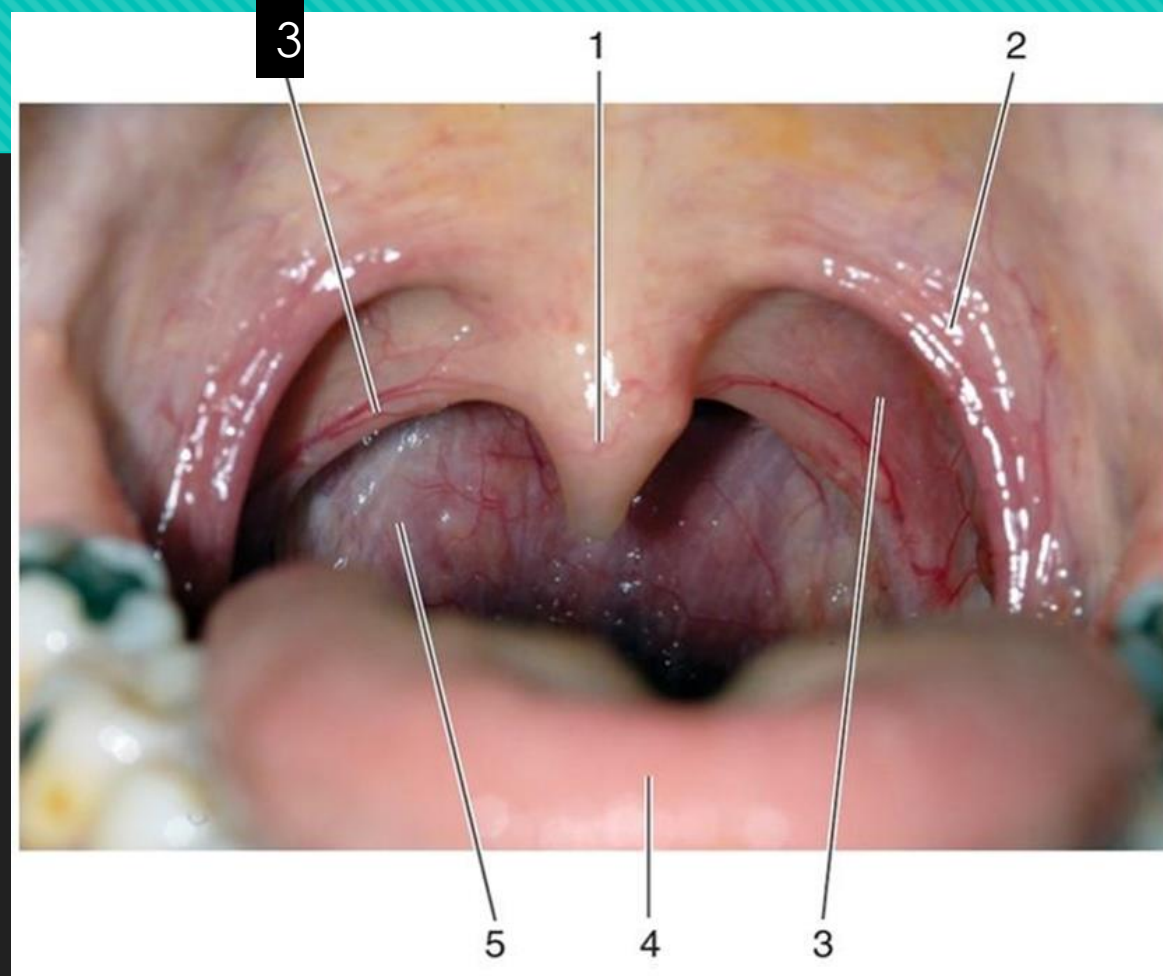
1 Uvula

2 Palatoglossal arch
(Anterior tonsillar pillar)

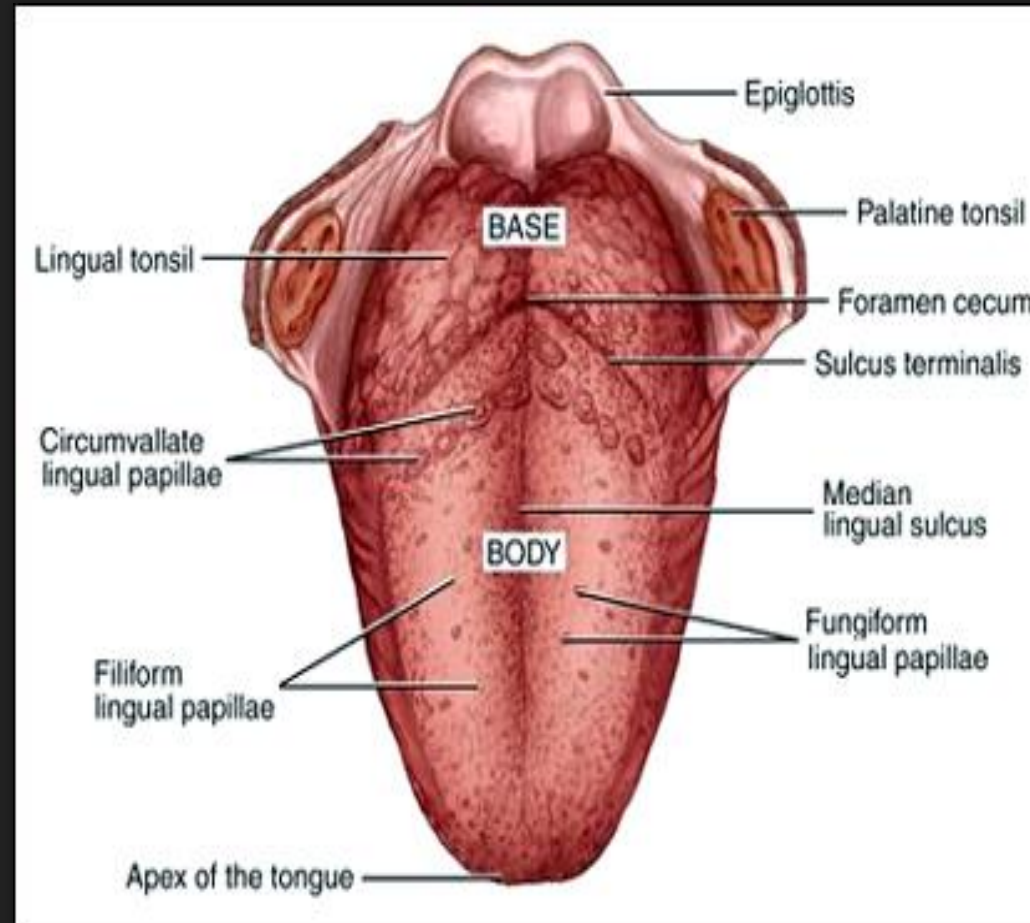
3 Palatopharyngeal arch
(Posterior tonsillar pillar)

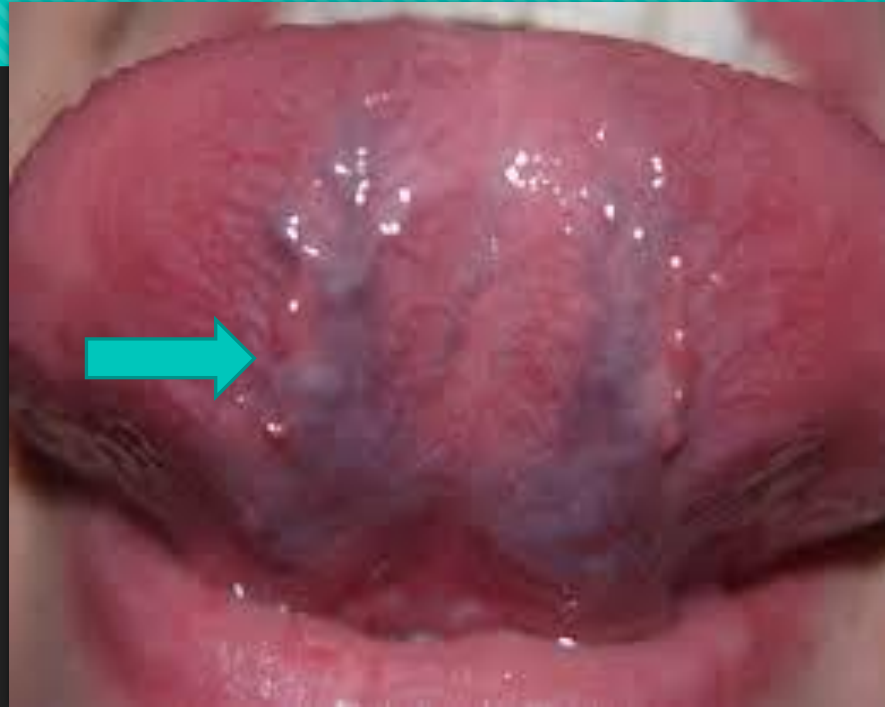4 Tongue

5 Retropharynx

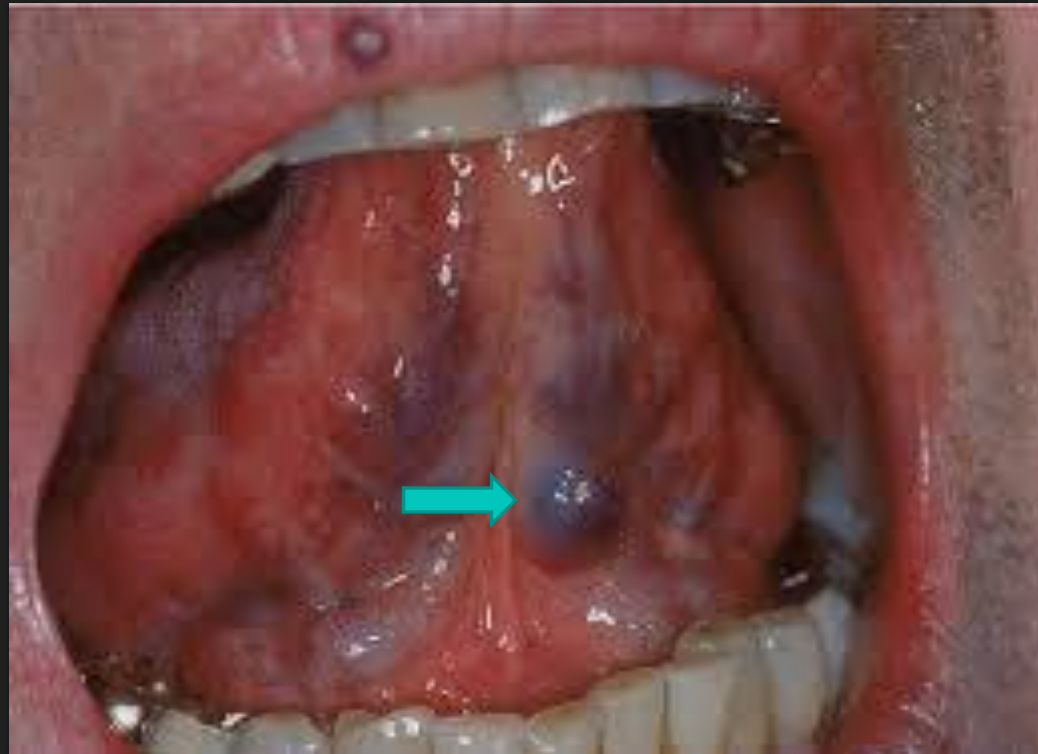

Tongue

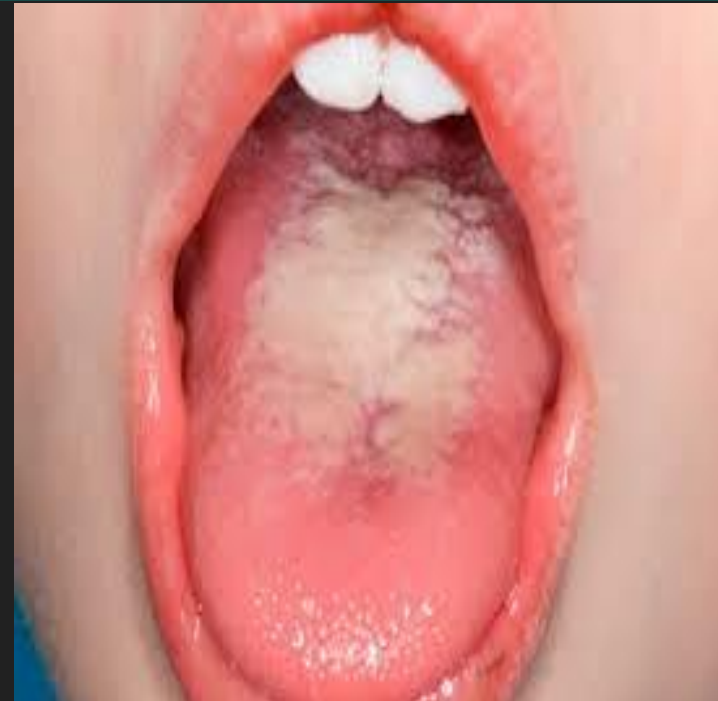
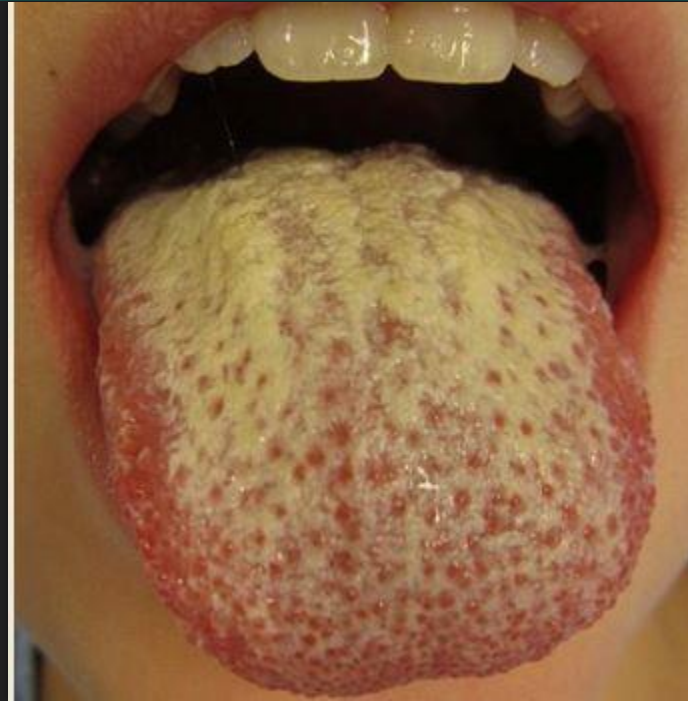


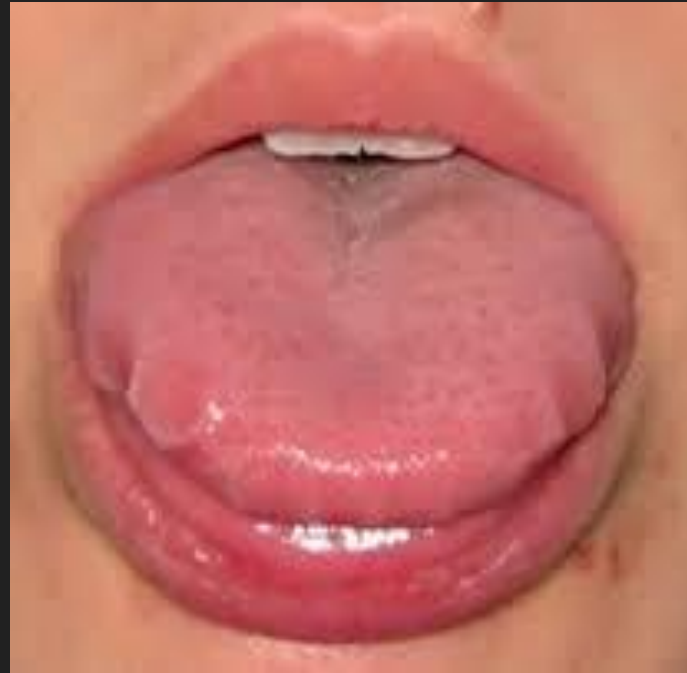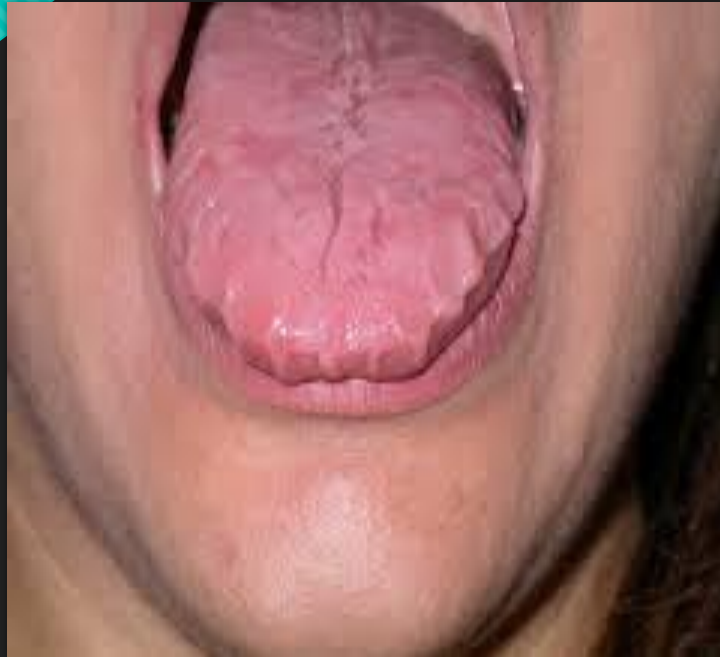varicose



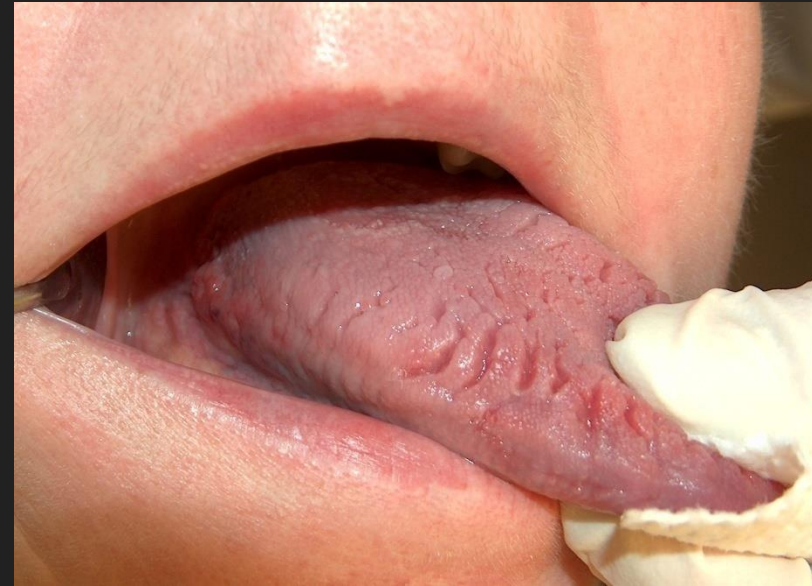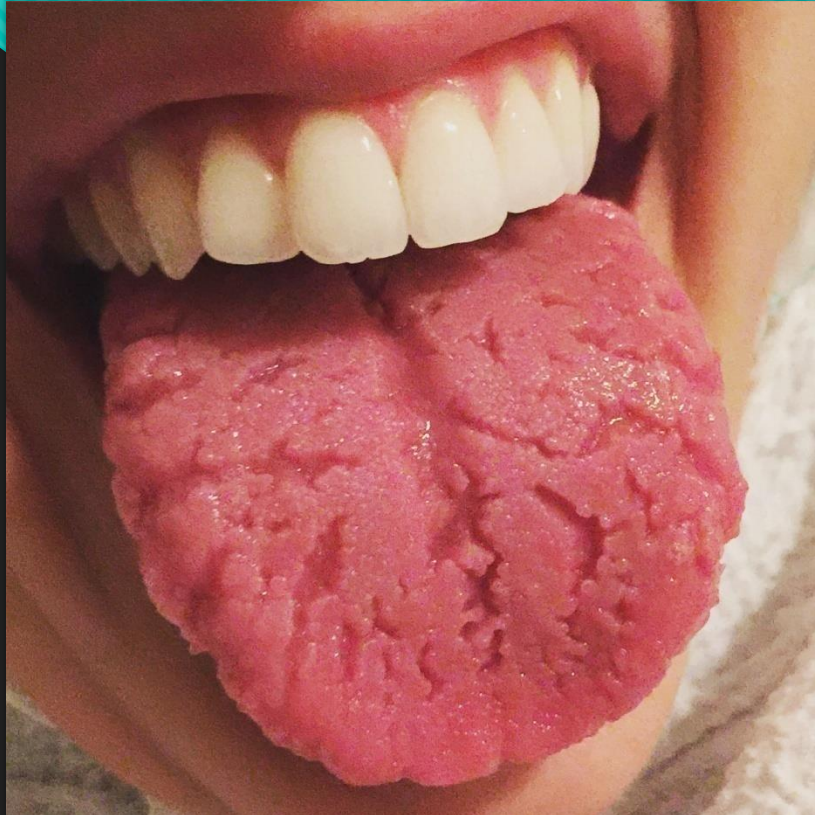Coated tongue



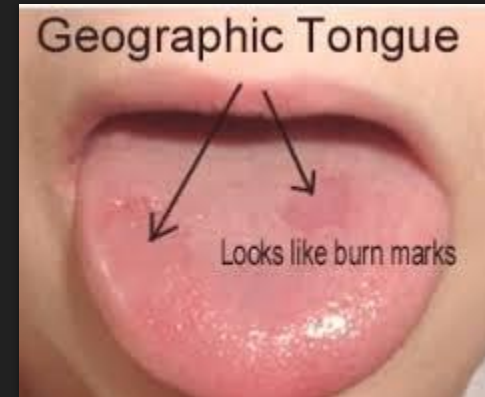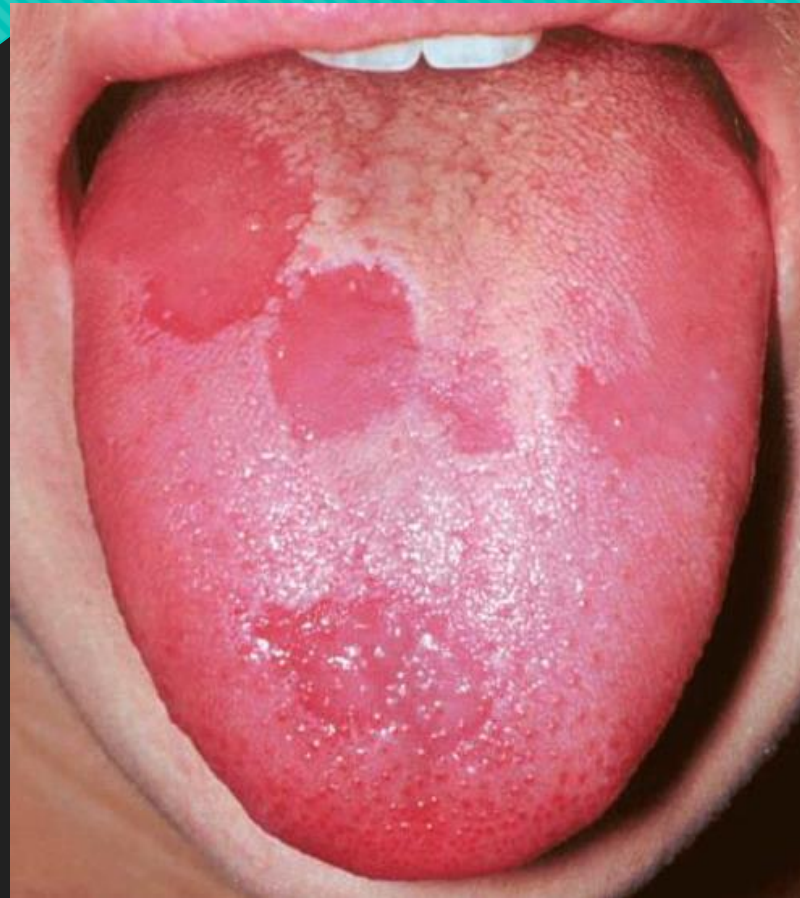Scalloped tongue

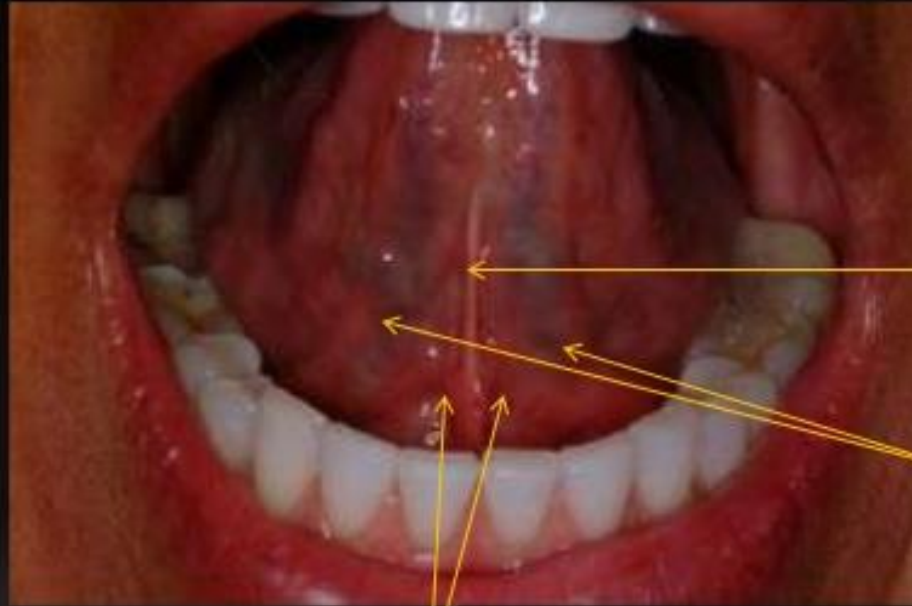


Fissured tongue (scrotal tongue)



Geographic tongue(erythema migrans)





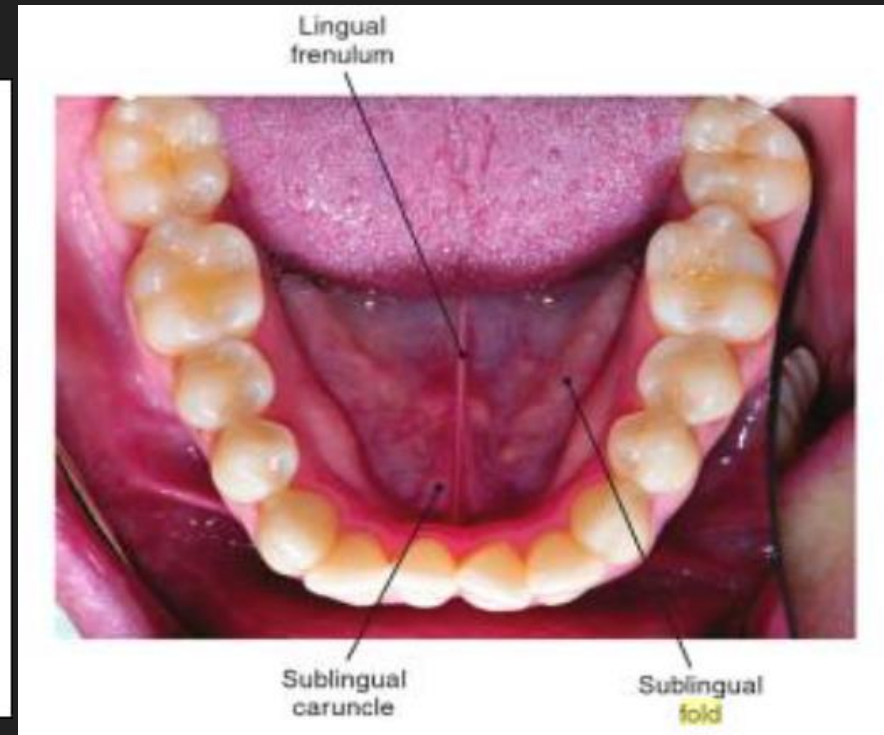
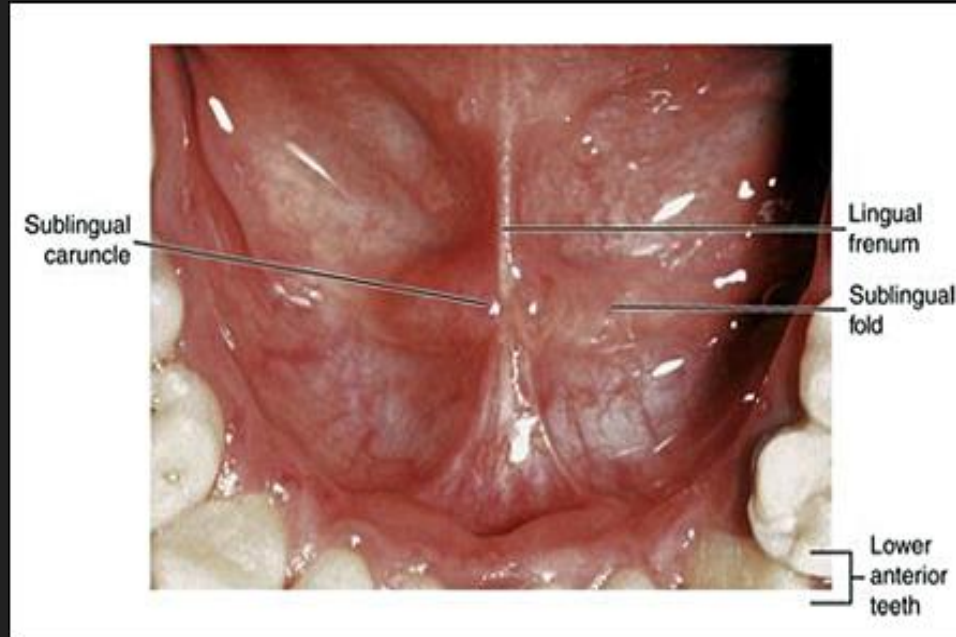
Lingual frenulum
(connects the tongue to the floor of the mouth)

Sublingual fold
(passes laterally and backwards from the papilla and overlies the sublingual gland)

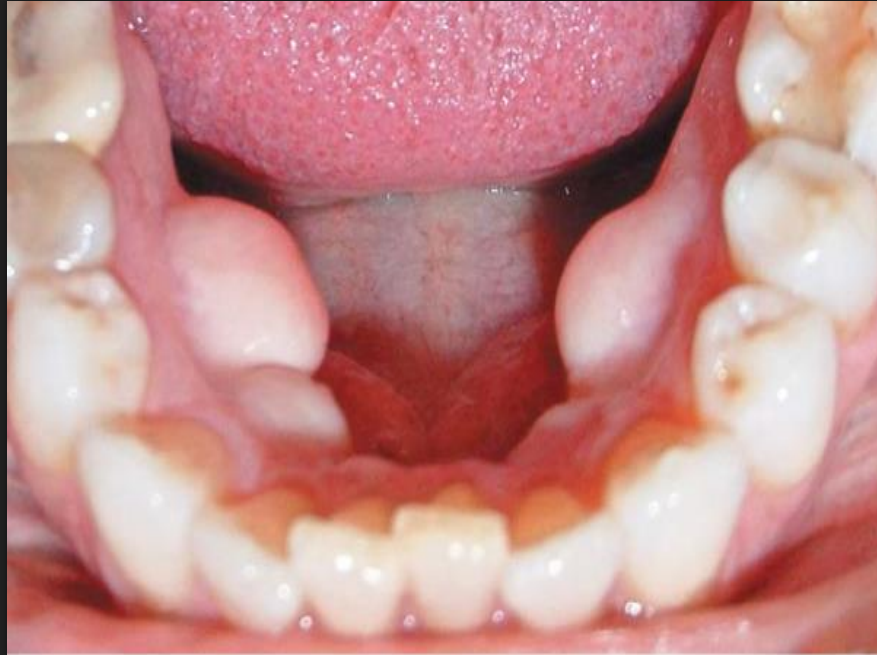Papillae (openings of submandibular duct)



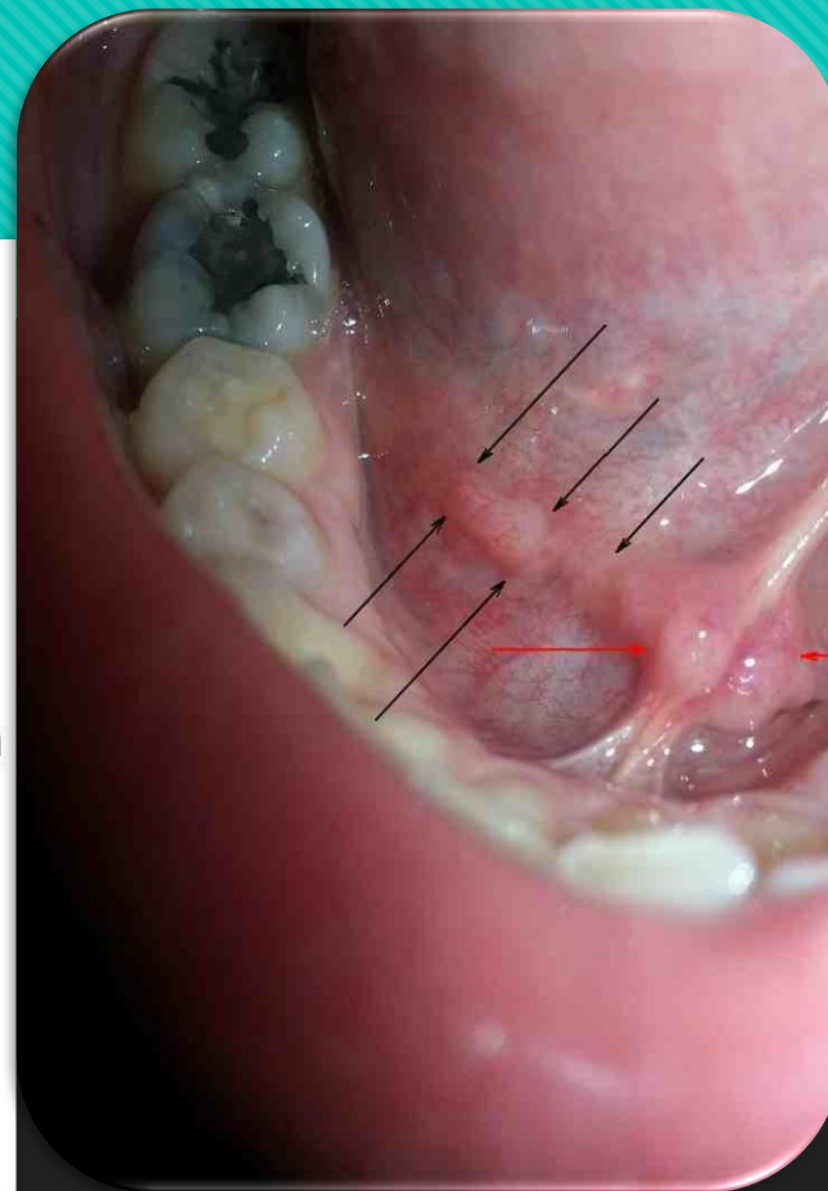
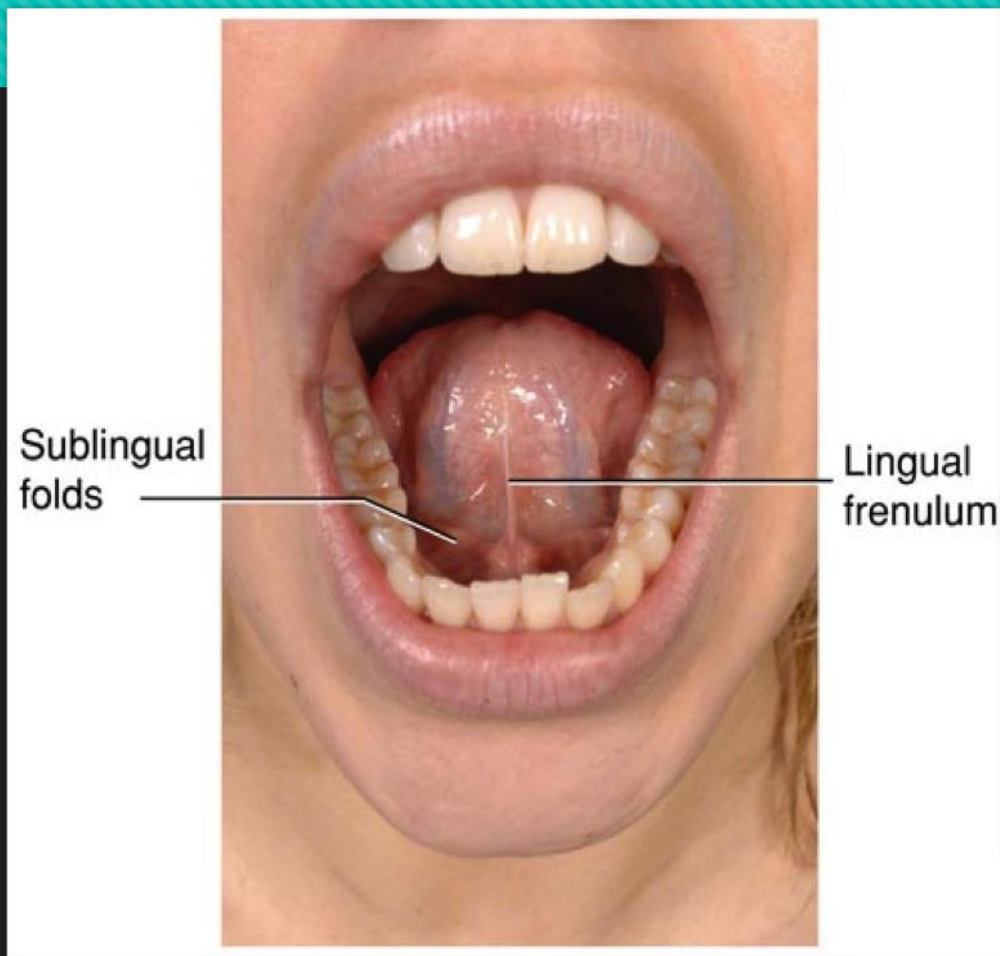
Floor of the mouth



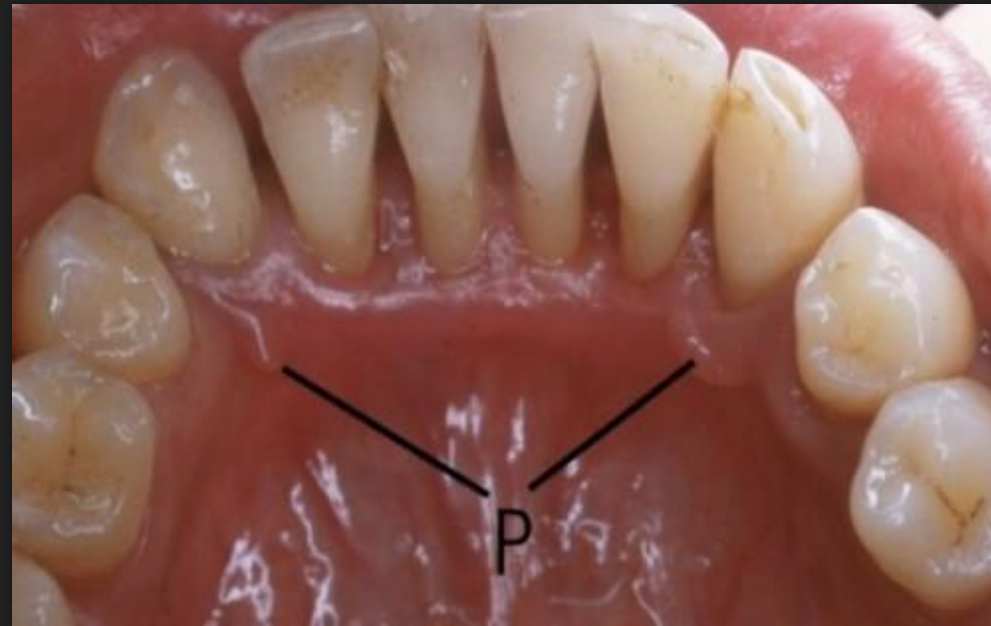
Torous mandibularis

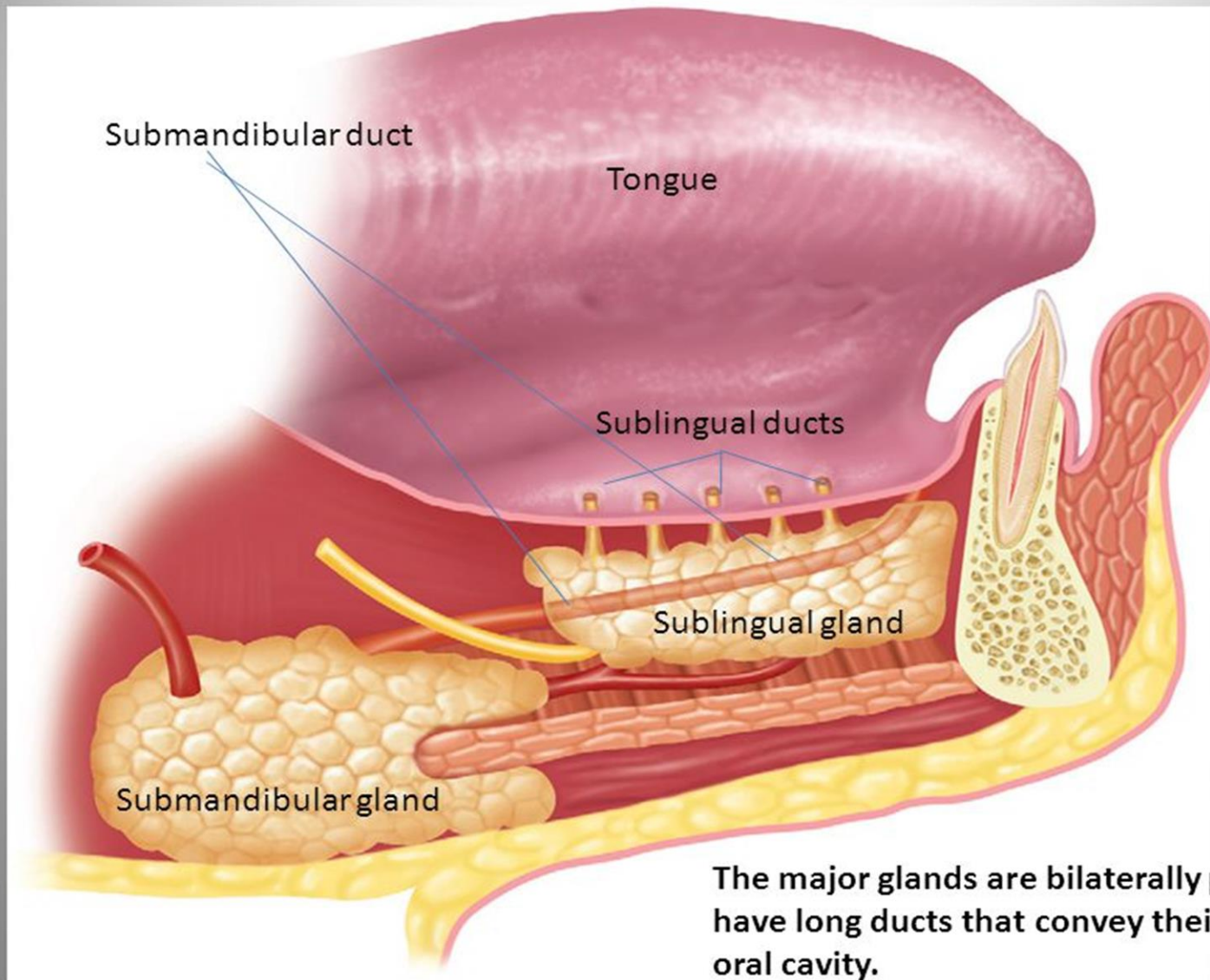


Sublingual fold



Retrocuspid papilla

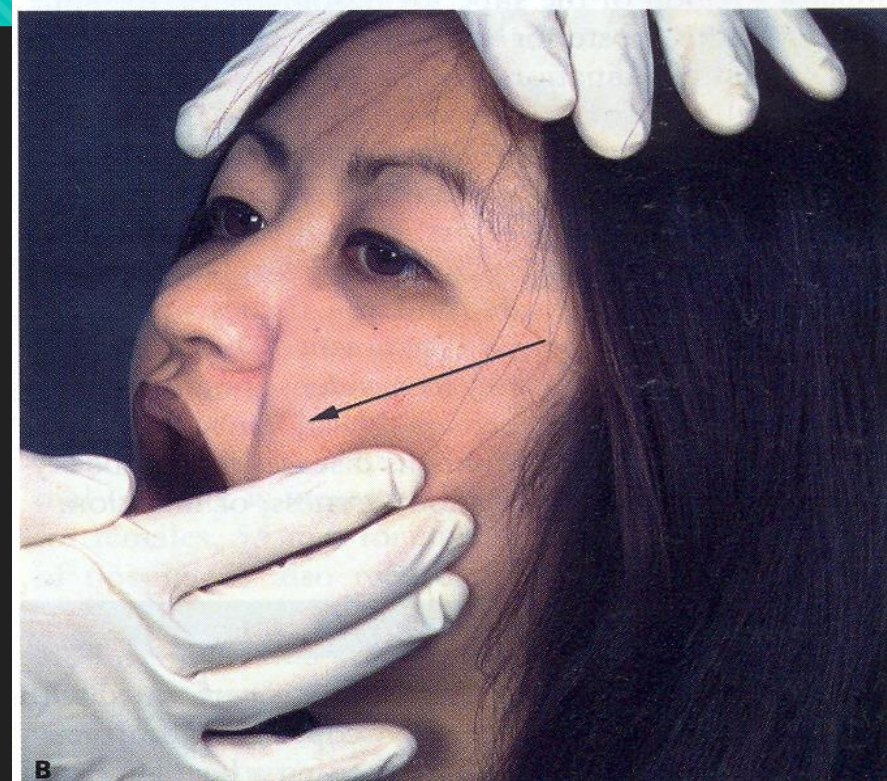
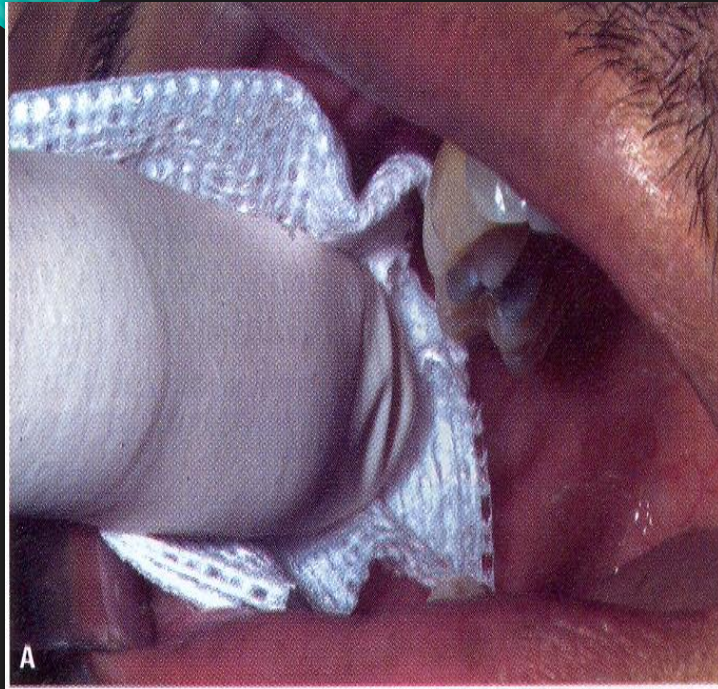




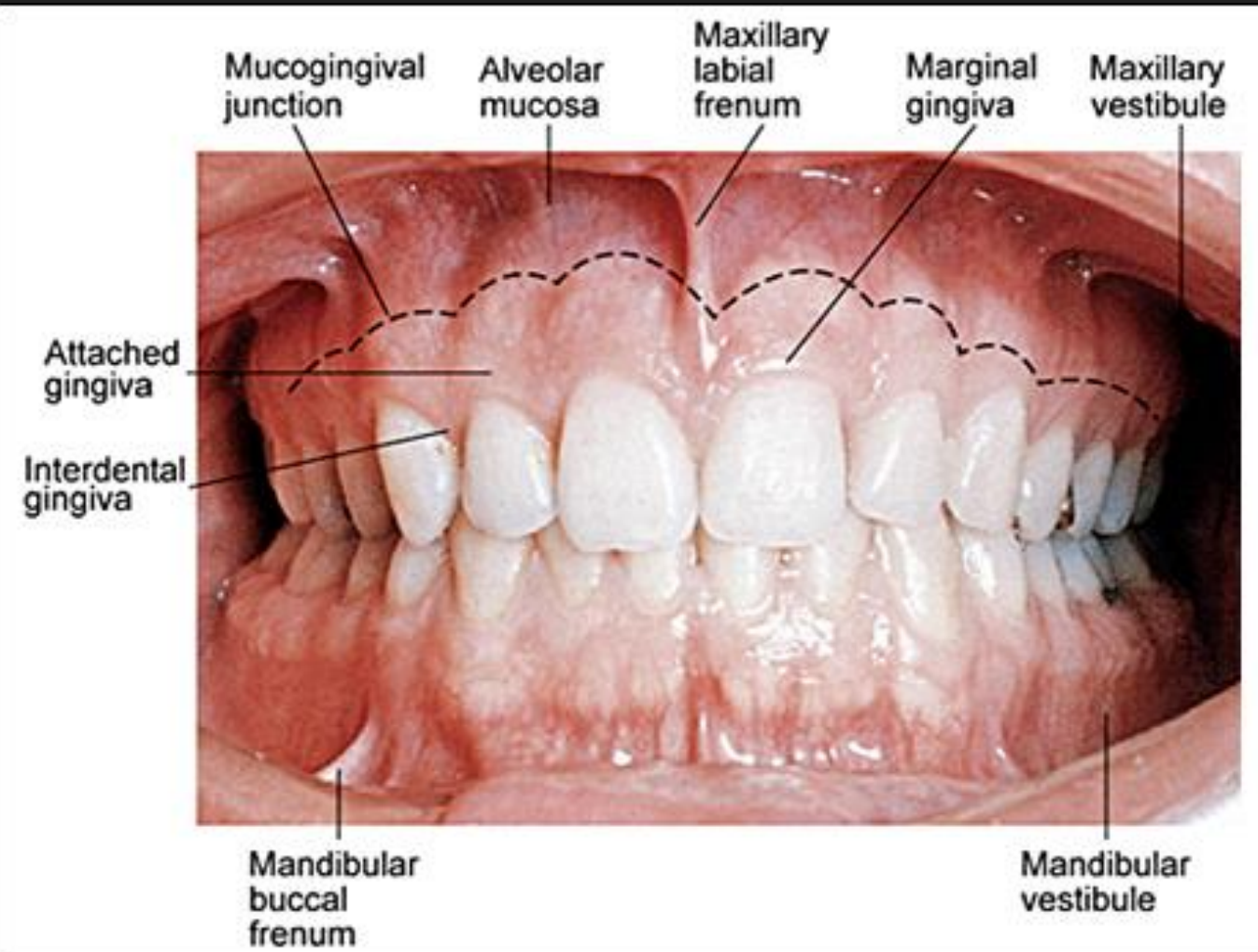
The major glands are bilaterally paired and have long ducts that convey their saliva to the oral cavity.



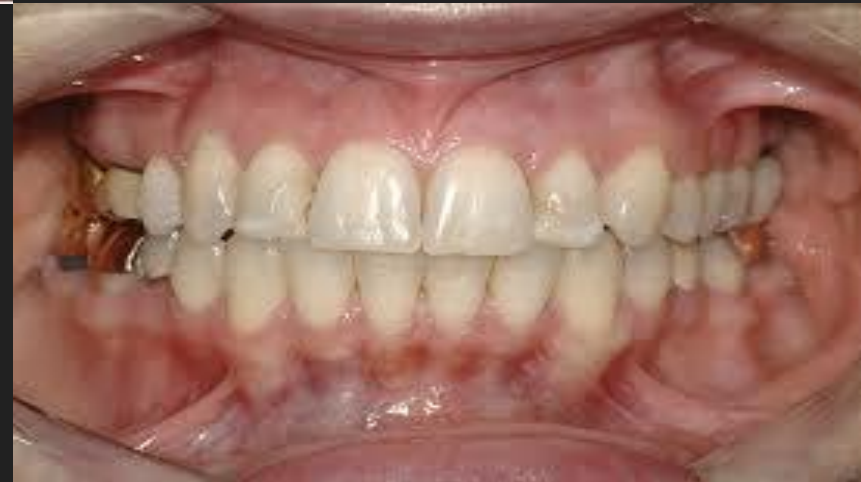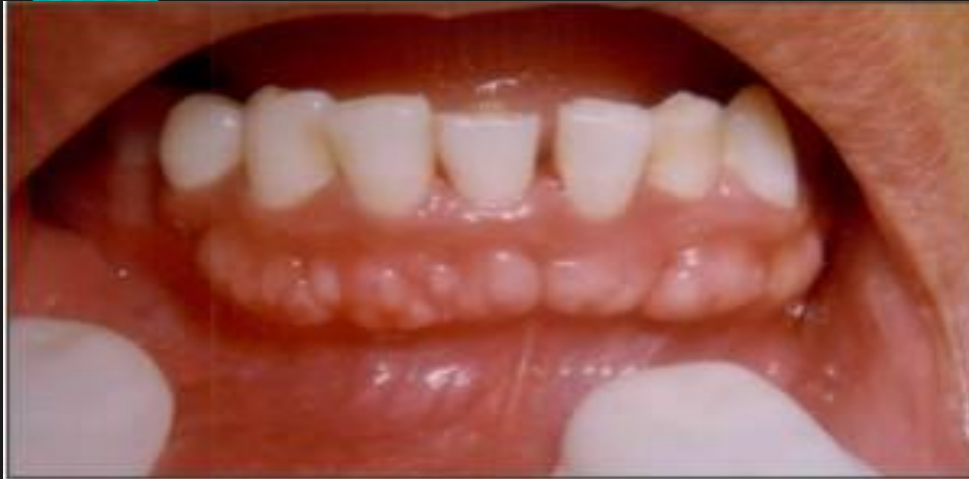Milking of salivary gland



Gingivae

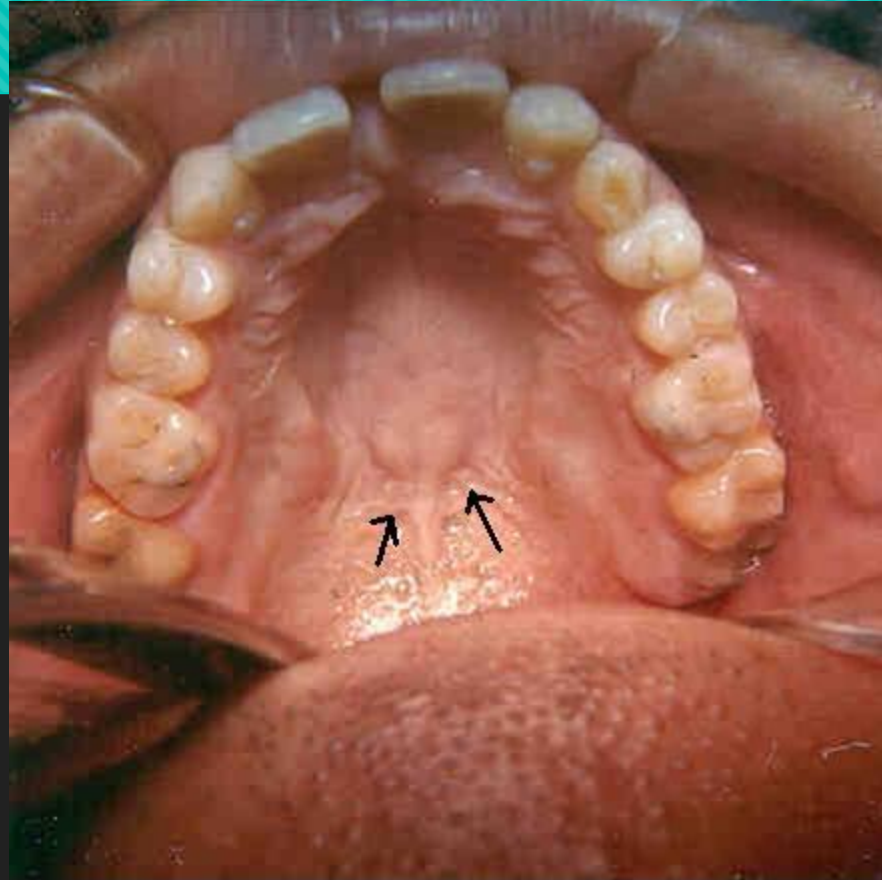
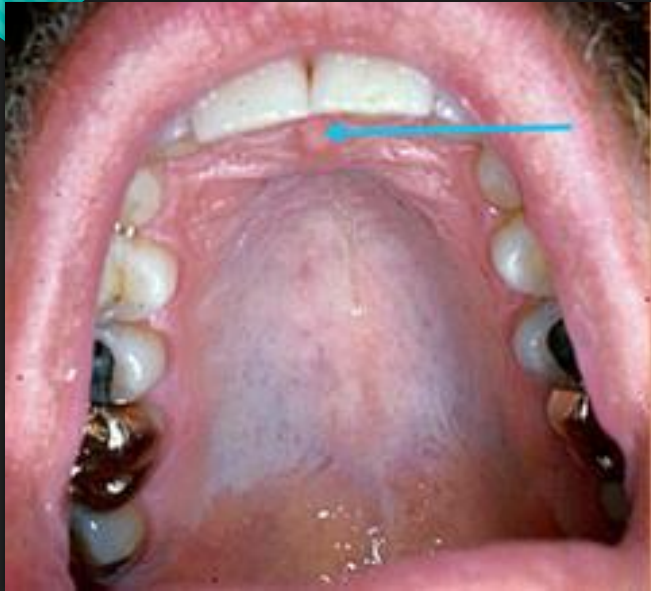

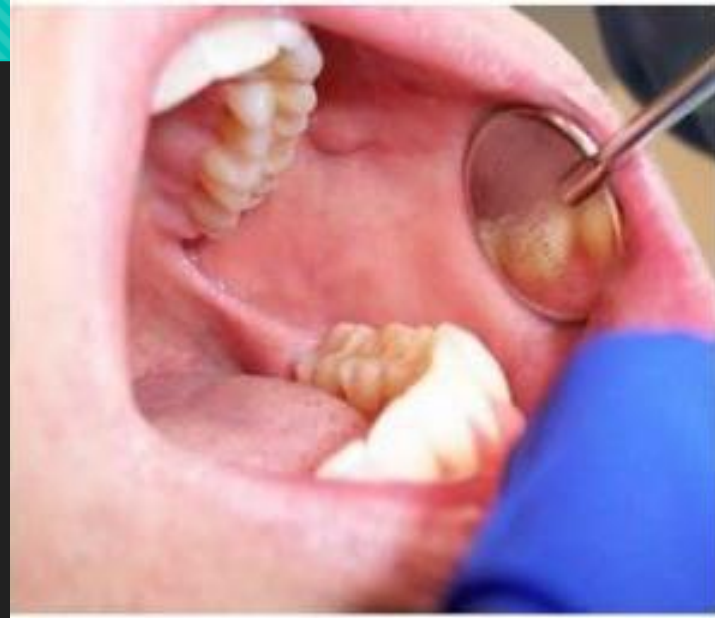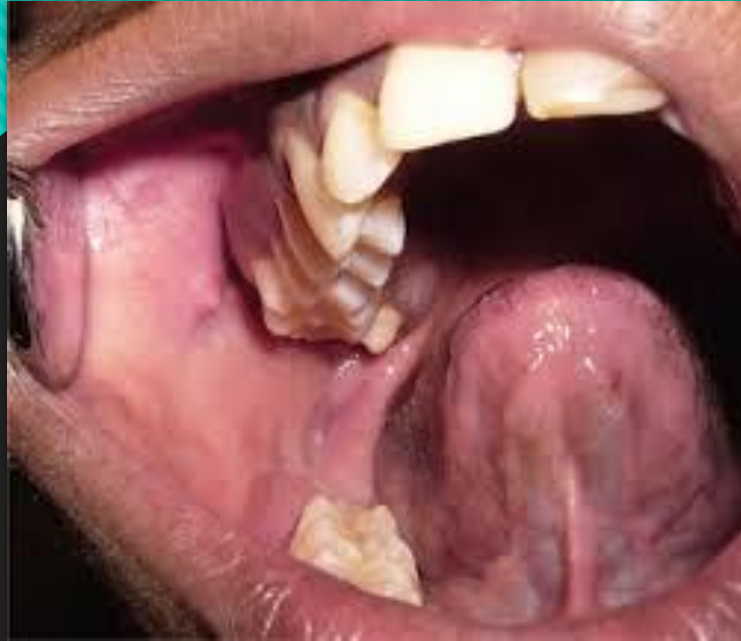Exostosis

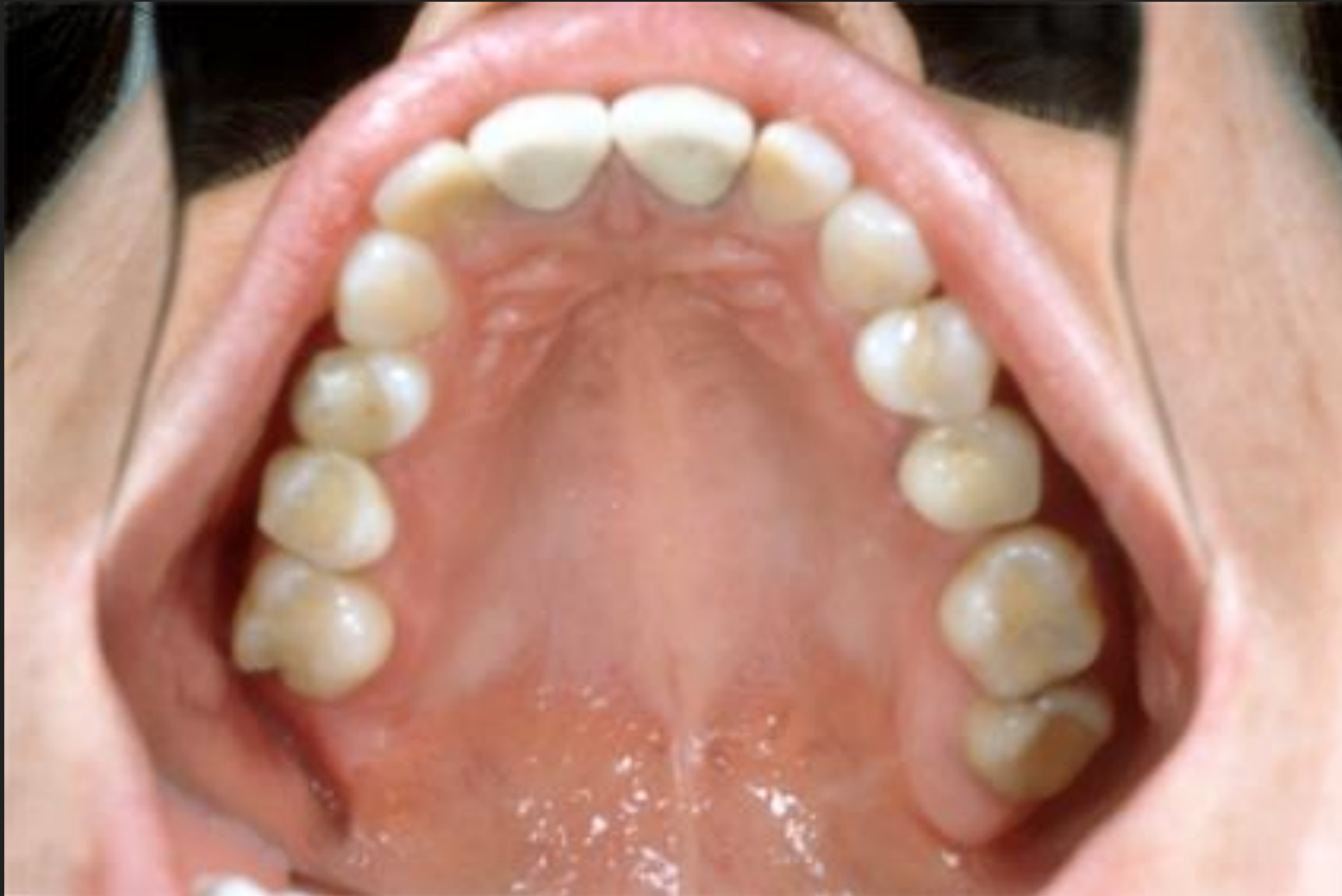

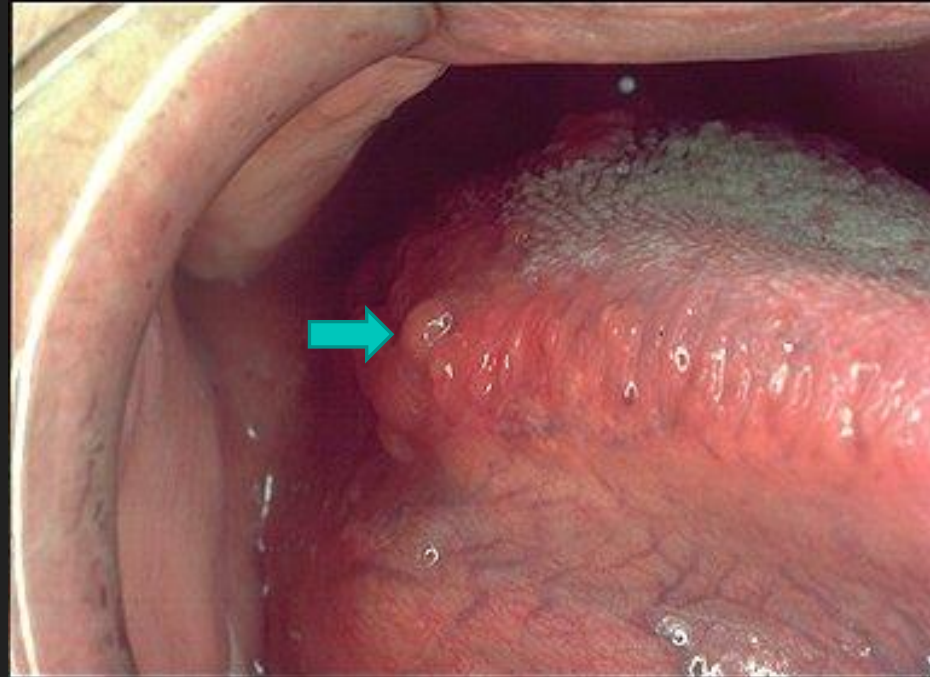
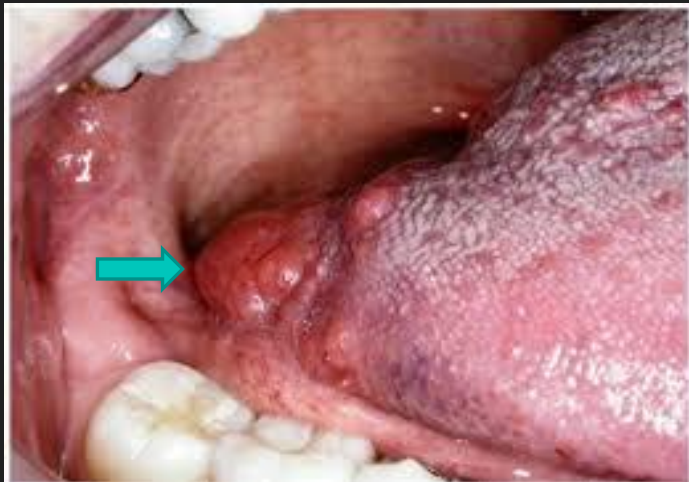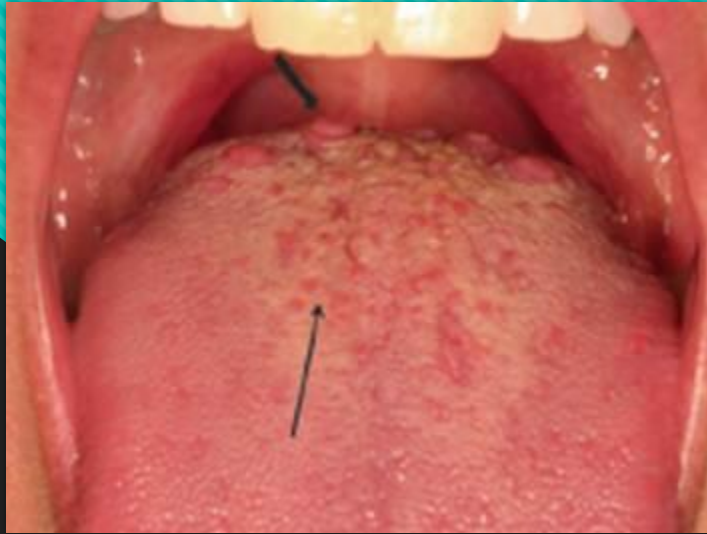Quiz

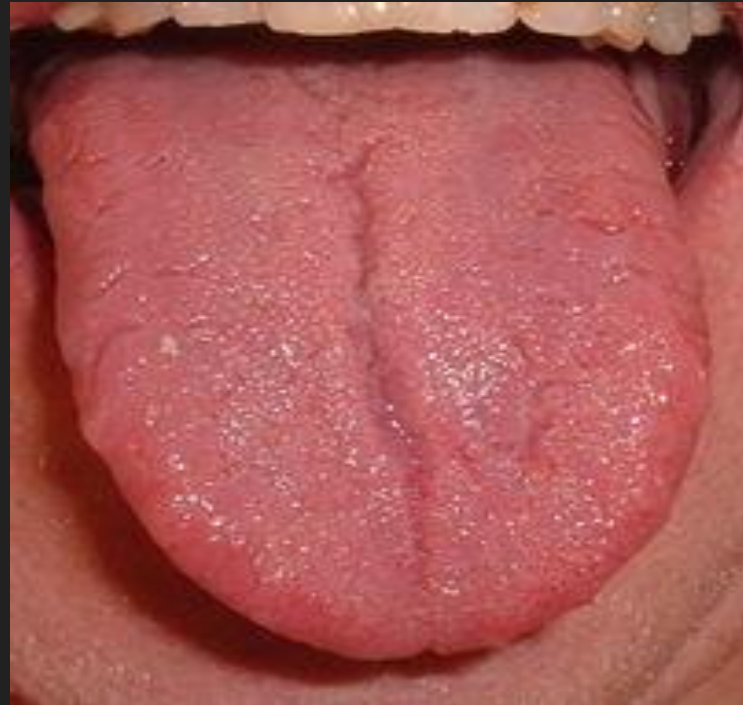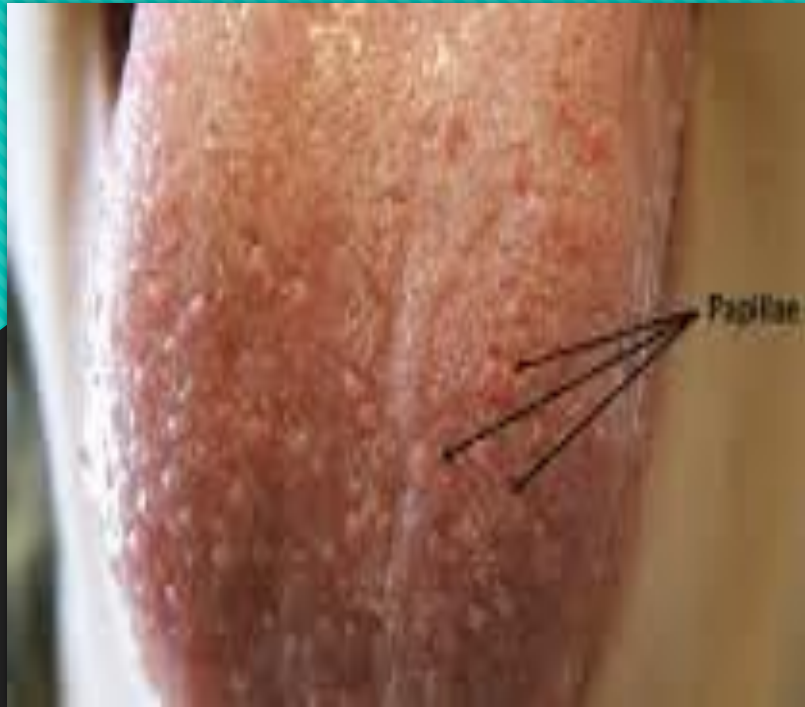○ در اسلایدهای بعد نواحی آناتومیک و نرمال وریشن ها را پیدا کنید.

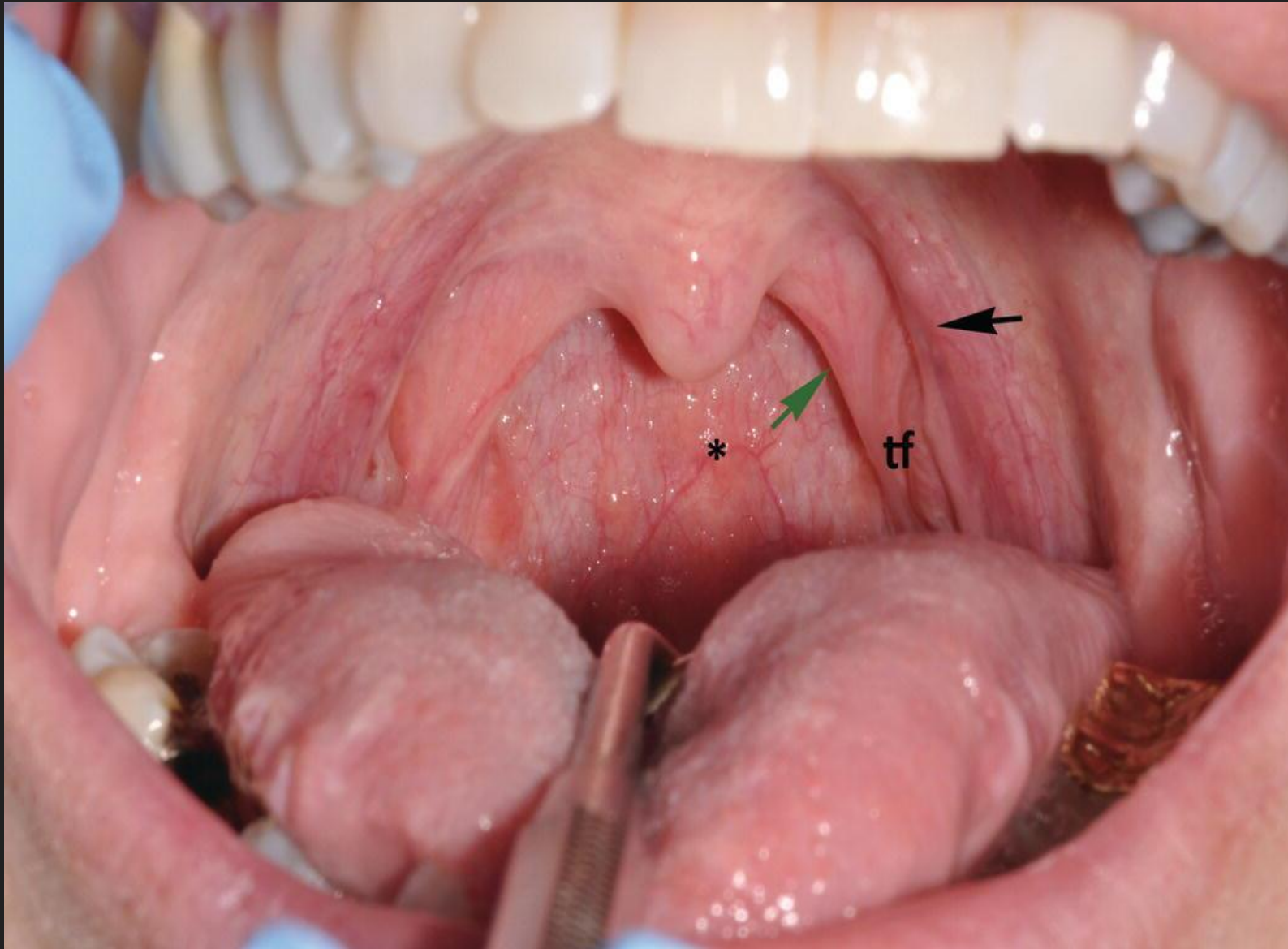


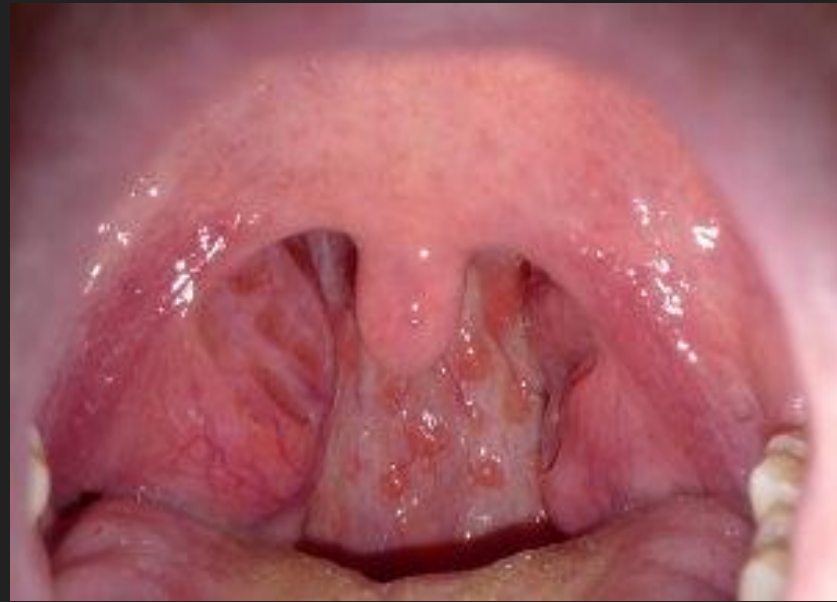
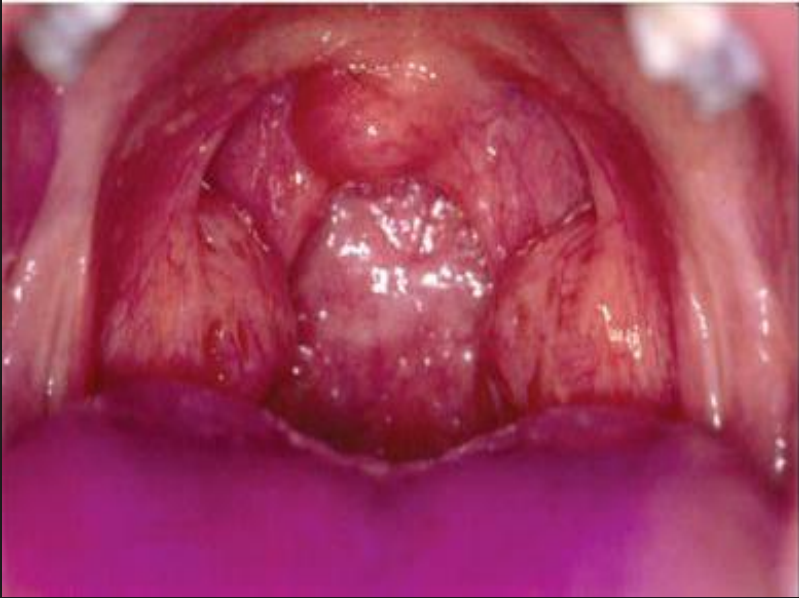
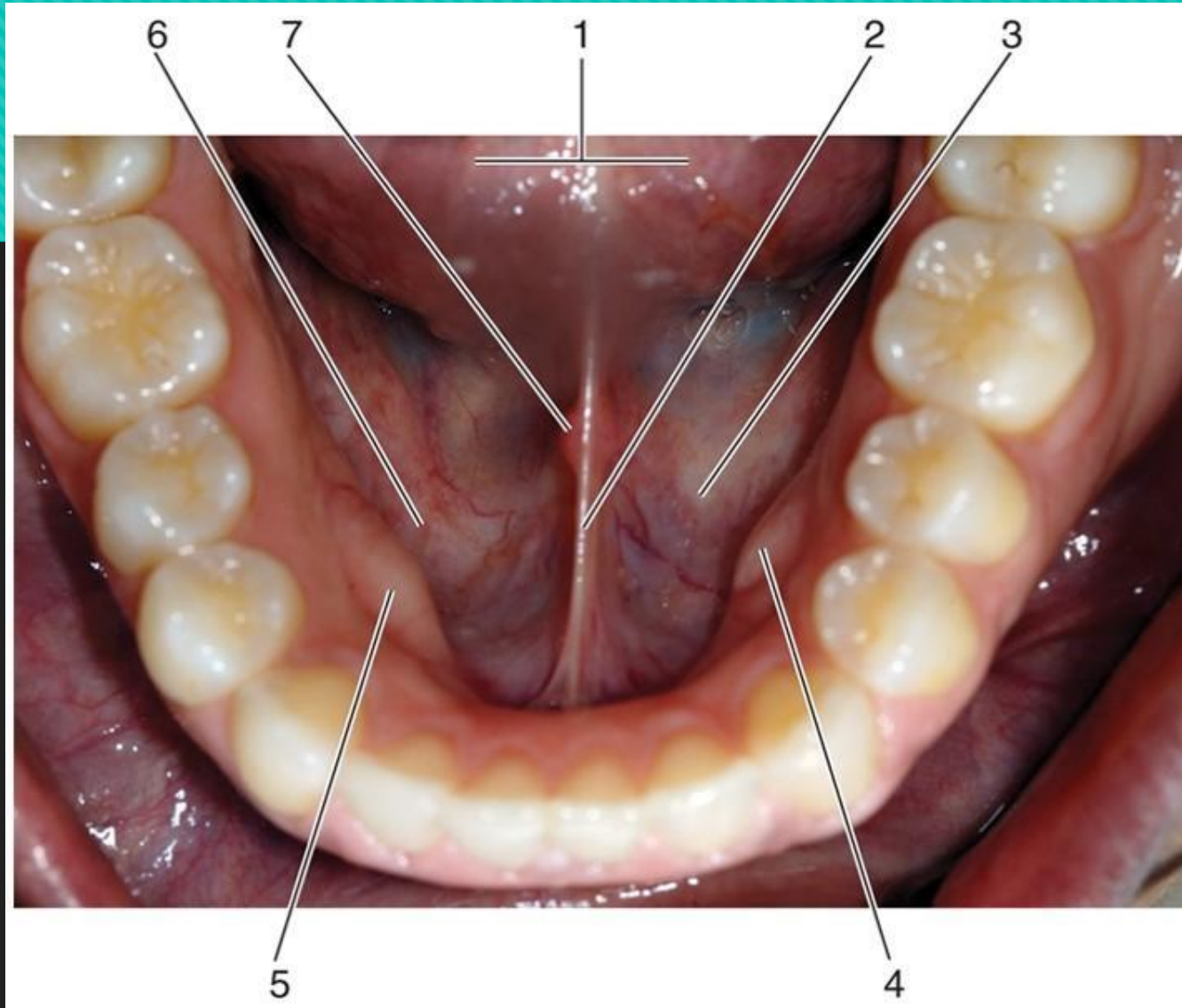




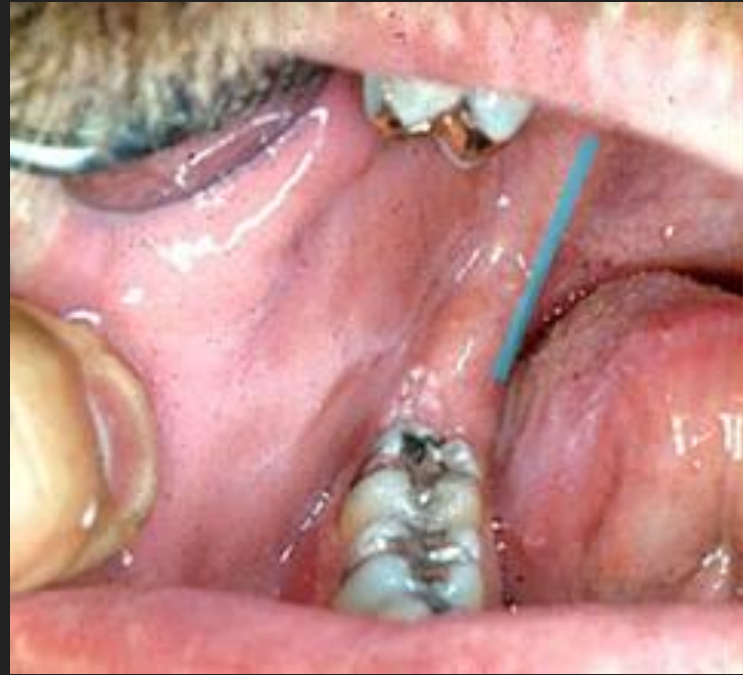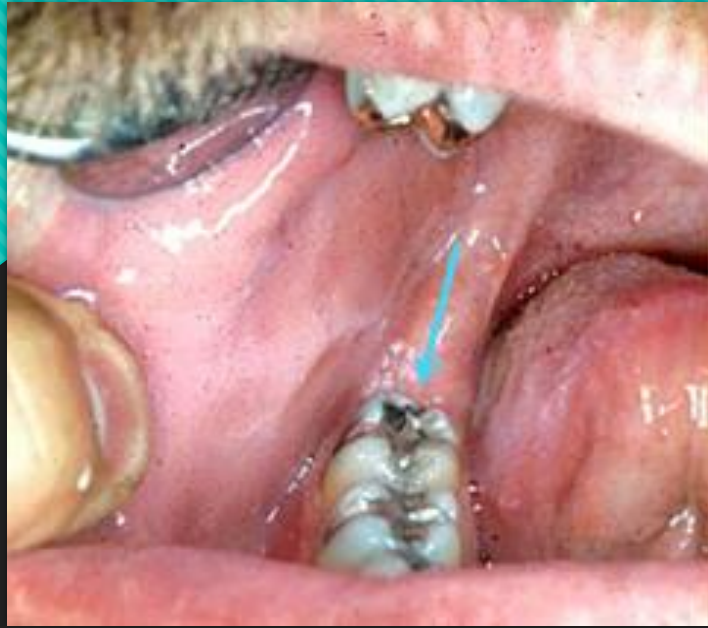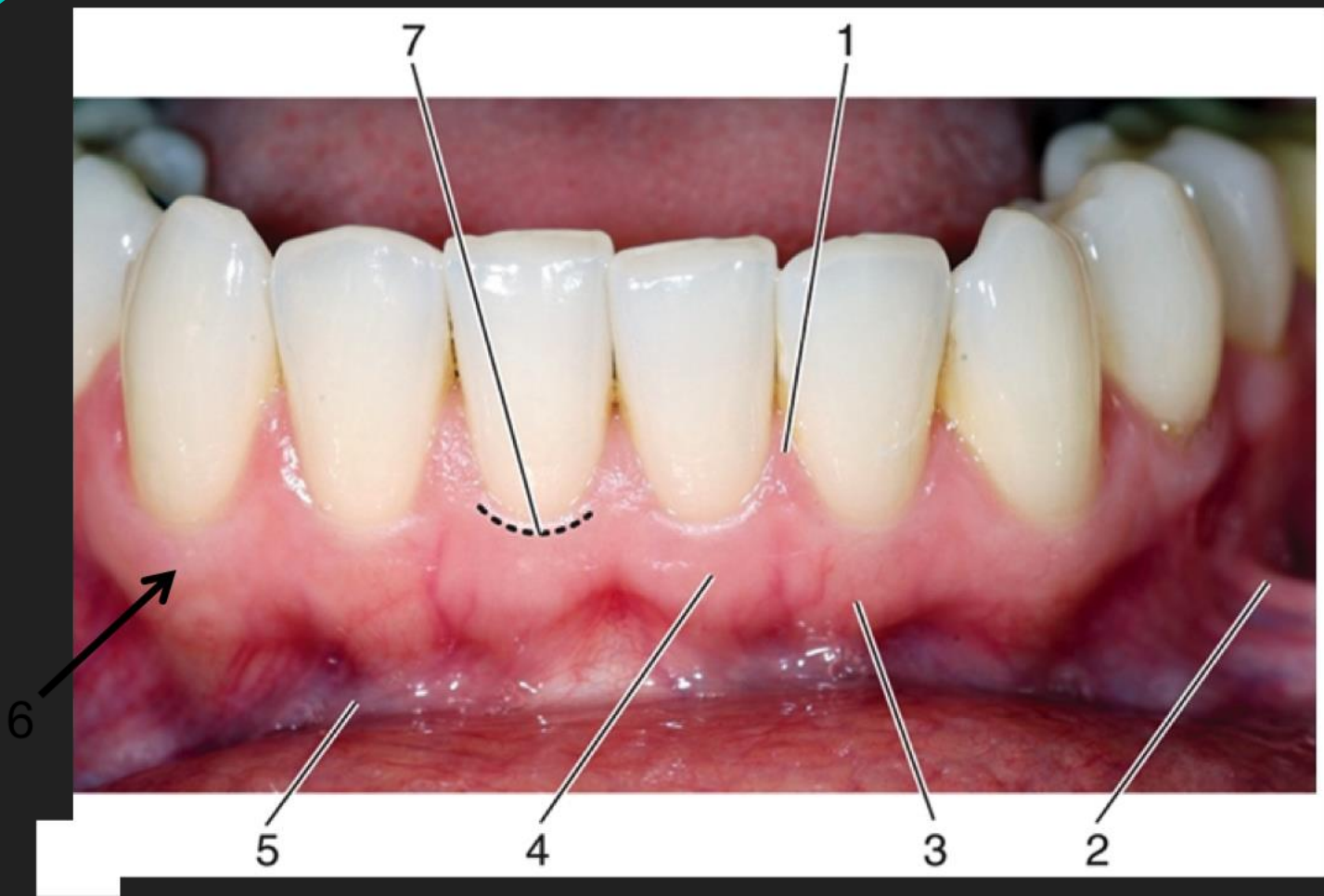




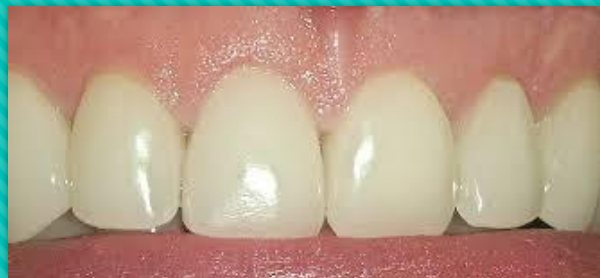







Thanks for Your Attention